

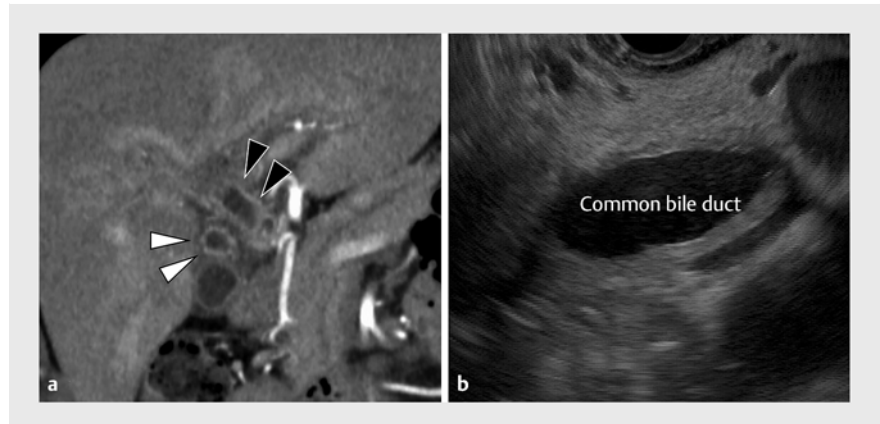


Clinical response in the haustra-like folds observed during peroral cholangioscopy following steroid therapy for immune checkpoint inhibitor-induced cholangitis

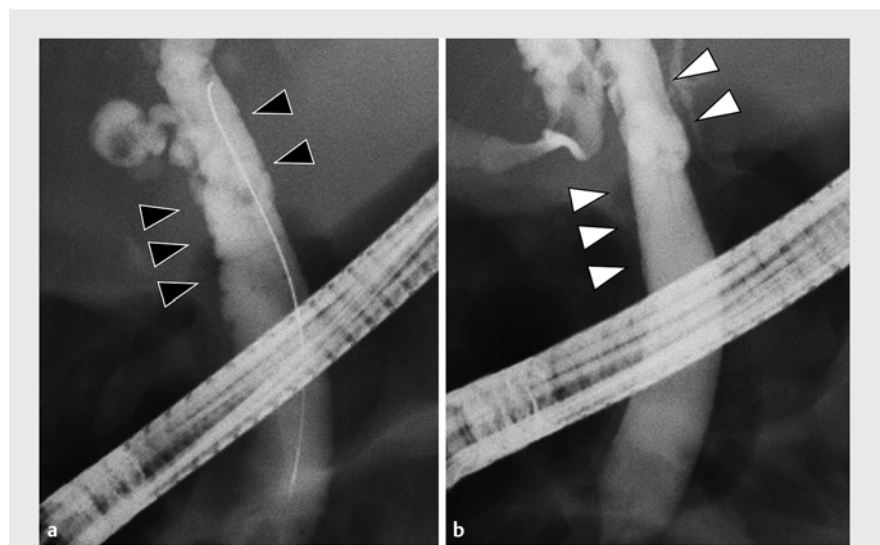
Immune-related adverse event (AE) cholangitis caused by immune checkpoint inhibitors is relatively rare (0.05%–3.3%), and steroids are an effective treatment [1]. Although some papers have reported the characteristic findings on peroral direct cholangioscopy [2], it is still unclear how to taper the steroid dose to best improve the condition.

A 70-year-old woman had epigastralgia and liver dysfunction. She had a history of lung cancer resection and had been treated with pembrolizumab for recurrence, which had been discontinued 4 months previously because of immune-related AE dermatitis. Computed tomography (CT) and endoscopic ultrasonography (EUS) revealed marked uniform and circumferential wall thickening in the distal bile duct (► **Fig. 1**). Cholangiography showed dilatation and wall irregularity in the extrahepatic bile duct (► **Fig. 2 a**). Peroral direct cholangioscopy showed diffuse redness and scattered mucosal stenoses, with an appearance similar to haustra (► **Video 1**). Bile duct biopsy revealed an inflammatory cell infiltration, mainly of lymphocytes, in the stroma. Moreover, immunohistochemistry confirmed that these lymphocytes were mainly CD8-positive T cells, compatible with immune-related AE cholangitis (► **Fig. 3 a, b**).

The patient was treated with oral prednisolone 25 mg (0.5 mg/kg) and, after 4 weeks, her abdominal pain and liver injury had significantly improved. After 8 weeks, repeat CT, EUS, and cholangiography showed marked improvement in the thickening and irregularity of the bile duct wall (► **Fig. 2 b**). The cholangioscopy showed a decrease in the height of haustra-like changes in the bile duct mucosa. The infiltrate of CD8-positive cells was however still seen in the biopsy (► **Fig. 3 c, d**). The patient has been maintained on 3 months of predni-



► **Fig. 1** Uniform and circumferential wall thickening is seen in the hilar bile duct on: **a** computed tomography (black arrowheads), along with a similar appearance in the cystic duct (white arrowheads); **b** endoscopic ultrasonography.

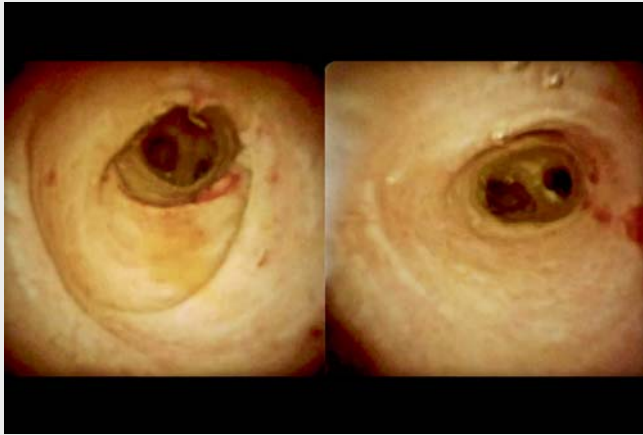


► **Fig. 2** Cholangiographic appearance showing: **a** dilatation of the extrahepatic bile duct and irregularity of the bile duct wall (black arrowheads); **b** marked improvement in the irregularity of the bile duct wall (white arrowheads) after 8 weeks of oral prednisolone.

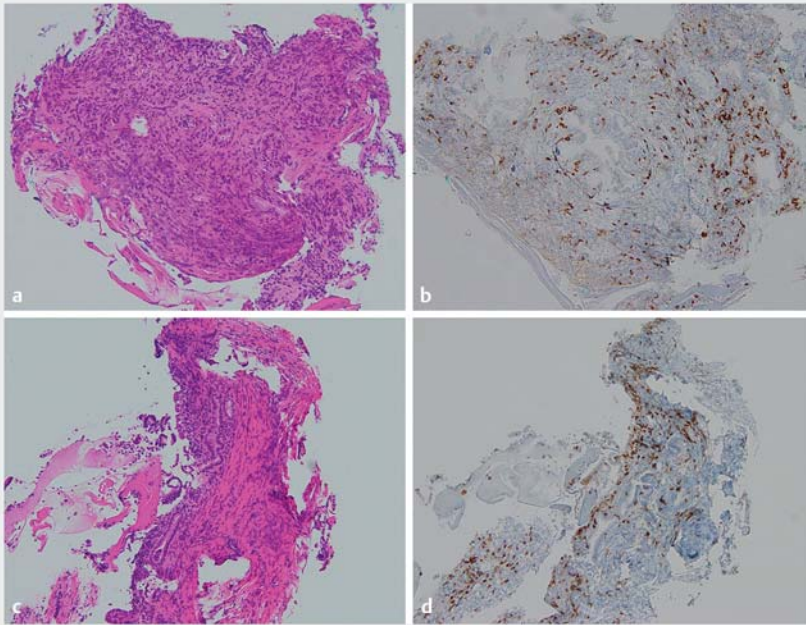
solone (5 mg), without experiencing a clinical relapse.

Various cholangioscopic findings have been reported in immune-related AE cholangitis, including ulceration with “burned-out” epithelium, diverticulum-

like findings, and membranous stenosis [3,4]. There have been no reports however that have compared these endoscopic findings after a therapeutic response. In this case, despite an improvement in the patient’s symptoms



▶ Video 1 Findings in a patient with immune-related adverse event cholangitis including peroral cholangioscopy that shows coarse mucosa with multiple erosions, vasodilation, and scattered membranous stenoses, which appear similar to haustra, with an improvement in both the imaging and endoscopic findings evident after 8 weeks of steroid therapy.



▶ Fig. 3 Histopathological findings of the bile duct biopsy on: **a, c** hematoxylin and eosin [H&E] staining; **b, d** immunohistochemical staining, showing: **a, b** an infiltrate of inflammatory cells in the stroma, consisting mainly of lymphocytes that are CD8-positive T cells; **c, d** ongoing infiltration in the biopsy after 8 weeks of oral prednisolone (all magnifications, $\times 40$).

and in the imaging findings after treatment, direct observation of the bile duct by cholangioscopy and the histopathological findings still showed residual inflammation. Tapering off steroids in immune-related AE cholangitis may be prudent.

Endoscopy_UCTN_Code_CCL_1AZ_2AZ

Competing interests

The authors declare that they have no conflict of interest.

The authors

Yoshiya Takeda¹, Osamu Inatomi¹, Shuhei Shintani¹, Takehide Fujimoto¹, Atsushi Nishida¹, Hiromu Kutsumi², Akira Andoh¹

- 1 Department of Medicine, Shiga University of Medical Science, Otsu, Japan
- 2 Department of Center for Clinical Research and Advanced Medicine, Shiga University of Medical Science, Otsu, Japan

Corresponding author

Osamu Inatomi, MD, PhD

Department of Medicine, Shiga University of Medical Science, Seta Tsukinowa, Otsu, Shiga 520-2192, Japan
osam@belle.shiga-med.ac.jp

References

- [1] Pi B, Wang J, Tong Y et al. Immune-related cholangitis induced by immune checkpoint inhibitors: a systematic review of clinical features and management. *Eur J Gastroenterol Hepatol* 2021; 33: e858–e867
- [2] Onoyama T, Takeda Y, Yamashita T et al. Programmed cell death-1 inhibitor-related sclerosing cholangitis: A systematic review. *World J Gastroenterol* 2020; 26: 353–365
- [3] Onoyama T, Takeda Y, Kato M et al. Peroral cholangioscopy of programmed cell death-1 inhibitor-related sclerosing cholangitis: three case reports. *Endoscopy* 2019; 51: E402–E403
- [4] Kuraoka N, Hara K, Terai S et al. Peroral cholangioscopy of nivolumab-related (induced) ulcerative cholangitis in a patient with non-small cell lung cancer. *Endoscopy* 2018; 50: E259–E261

Bibliography

Endoscopy

DOI 10.1055/a-1899-8619

ISSN 0013-726X

published online 2022

© 2022. The Author(s).

This is an open access article published by Thieme under the terms of the Creative Commons Attribution-NonDerivative-NonCommercial License, permitting copying and reproduction so long as the original work is given appropriate credit. Contents may not be used for commercial purposes, or adapted, remixed, transformed or built upon. (<https://creativecommons.org/licenses/by-nc-nd/4.0/>)

Georg Thieme Verlag KG, Rüdigerstraße 14, 70469 Stuttgart, Germany

