



Correction to: Relationship between retinal fluid and visual acuity in patients with exudative age-related macular degeneration treated with intravitreal aflibercept using a treat-and-extend regimen: subgroup and post-hoc analyses from the ALTAIR study

Masahito Ohji¹ · Annabelle A. Okada² · Koji Sasaki³ · SungChul Charles Moon³ · Tobias Machewitz⁴ · Kanji Takahashi⁵ · on behalf of the ALTAIR Investigators

© The Author(s) 2022

Correction to: Graefe's Archive for Clinical and Experimental Ophthalmology (2021) 259:3637–3647

<https://doi.org/10.1007/s00417-021-05293-y>

The original version of this article unfortunately contained errors. The corrections are given in the following list:

1. In Fig. 5A, the patient group with “Any fluid” at the non-foveal location incorrectly also included a few patients whose fluid presence is unknown. The corresponding non-foveal data have been re-evaluated and Fig. 5A amended. Specifically, data for the number of patients, mean BCVA, and 95% confidence intervals have been updated for the bars representing non-foveal fluid at weeks 16, 52, and 96. The correct data are now presented in Fig. 5A.
2. In Fig. 5, it was also not specified that the footnotes “Missing for each fluid compartment ($n=2$)” and “Unknown for IRF ($n=3$)” were at baseline (not at other timepoints). The Fig. 5 footnote has now been corrected to clarify that these cases were at baseline.

The correct figure and legend are shown below. Revisions are shown in green for ease of reference.

This is being corrected in this publication.

Open Access This article is licensed under a Creative Commons Attribution 4.0 International License, which permits use, sharing, adaptation, distribution and reproduction in any medium or format, as long as you give appropriate credit to the original author(s) and the source, provide a link to the Creative Commons licence, and indicate if changes were made. The images or other third party material in this article are included in the article's Creative Commons licence, unless indicated otherwise in a credit line to the material. If material is not included in the article's Creative Commons licence and your intended use is not permitted by statutory regulation or exceeds the permitted use, you will need to obtain permission directly from the copyright holder. To view a copy of this licence, visit <http://creativecommons.org/licenses/by/4.0/>.

Publisher's note Springer Nature remains neutral with regard to jurisdictional claims in published maps and institutional affiliations.

The original article can be found online at <https://doi.org/10.1007/s00417-021-05293-y>.

✉ Masahito Ohji
eye.ohji@gmail.com

¹ Department of Ophthalmology, Shiga University of Medical Science, Shiga, Japan

² Department of Ophthalmology, Kyorin University School of Medicine, Tokyo, Japan

³ Bayer Yakuhin Ltd., Osaka, Japan

⁴ Bayer AG, Berlin, Germany

⁵ Department of Ophthalmology, Kansai Medical University, Osaka, Japan

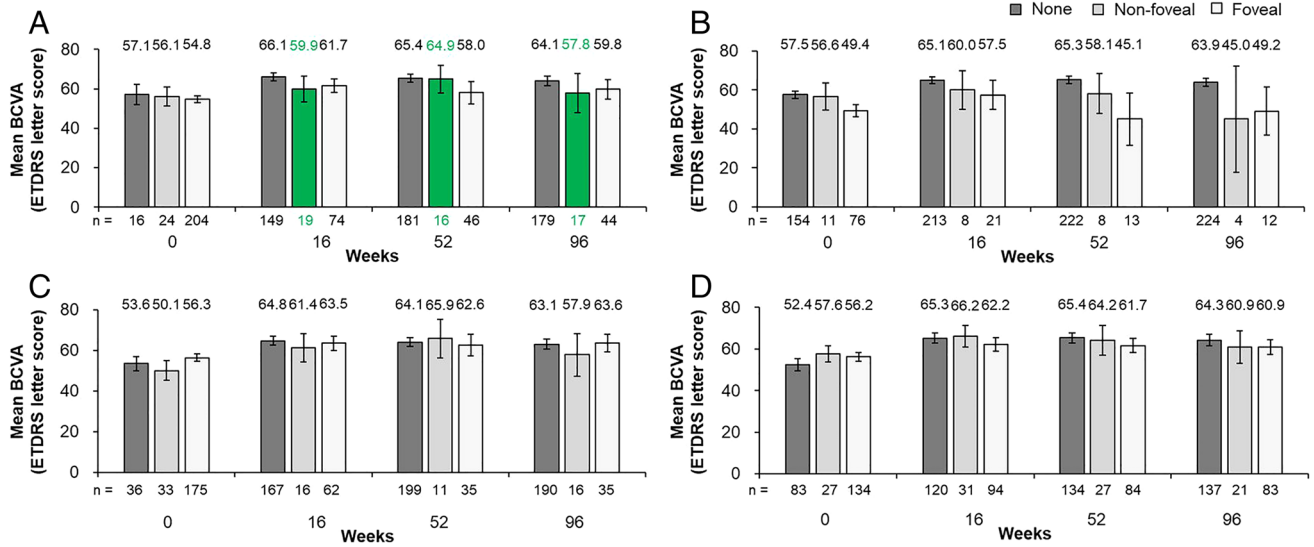


Fig. 1 Mean absolute BCVA (ETDRS letters) and 95% confidence intervals at mandatory study visits at weeks 0, 16, 52, and 96 in **A** patients without or with any foveal or non-foveal fluid,^a **B** patients without or with any foveal or non-foveal IRF, **C** patients without or with any foveal or non-foveal SRF, and **D** patients without or with any foveal or non-foveal PED. Full analysis set (N=246).^{b,c} The

number underneath each bar represents the number of patients in each group at each study visit. ^aIncludes IRF and SRF only; ^bMissing for each fluid compartment at baseline (n=2); ^cUnknown for IRF at baseline (n=3). BCVA, best-corrected visual acuity; ETDRS, Early Treatment Diabetic Retinopathy Study; IRF, intraretinal fluid; PED, pigment epithelial detachment; SRF, subretinal fluid