

[CASE REPORT]

Acquired Coagulation Factor V Inhibitor That Was Successfully Treated with Oral Corticosteroid Therapy

Yoshihiro Yokota¹, Osamu Inatomi², Minami Nakagawa³, Kazuki Kakuda¹, Kousuke Hiroe¹, Shigeki Sakai¹, Rie Osaki¹, Masaki Iwasa², Masahiro Kawahara², Katsuyuki Kito², Akira Andoh² and Hiromichi Bamba¹

Abstract:

Acquired coagulation factor V (FV) inhibitors are rare disorders in which antibodies against FV develop under various conditions. We herein report the case of a 71-year-old woman with FV inhibitor during radiochemotherapy for pancreatic cancer. Multiple purpuras suddenly appeared on her bilateral upper limbs with prolonged coagulation data (APTT 97.3 seconds). The FV activity was less than 3% and the FV inhibitor was positive (1.7 B.U./mL). Oral prednisolone induced a rapid normalization of the coagulation data and FV activity and a rapid disappearance of FV inhibitor within 7 days. Early diagnosis and treatment may therefore be important in cases of FV inhibitor.

Key words: factor V inhibitor, pancreatic cancer, corticosteroids

(Intern Med 60: 2663-2666, 2021)

(DOI: 10.2169/internalmedicine.7453-21)

Introduction

Acquired coagulation factor V (FV) inhibitors are rare disorders in which antibodies against FV develop in association with various causes including medications, malignancies, autoimmune disorders, pregnancy, infections, and unknown causes in up to 20% of cases (1). Their clinical manifestations vary from asymptomatic laboratory abnormalities to potentially life-threatening bleeding (1, 2). The precise mechanisms underlying their onset remain unclear, although the topical use of bovine thrombin during surgical treatment has historically been considered to be the most suspicious factor (3). The management of patients with FV inhibitors includes control of bleeding and eradication of the inhibitor (3). We herein report a case of FV inhibitor during radiochemotherapy for advanced pancreatic cancer, who was successfully treated with oral prednisolone.

Case Report

A 71-year-old woman was diagnosed with inoperative advanced pancreatic cancer in May 2019. She had no history of surgical treatment, bleeding tendency and no family history of bleeding disorder. She received anti-cancer chemotherapy consisting of gemcitabine plus S-1 (oral fluoropyrimidine) followed by gemcitabine plus nab-paclitaxel. Due to obstruction of the common bile duct by cancer invasion, she received endoscopic biliary drainage with plastic stent placement in December 2019 and percutaneous transhepatic biliary drainage in June 2020. As a treatment for recurrent biliary tract infection, she received several antibiotics such as sulbactam/cefoperazone, meropenem, and levofloxacin during the previous one year.

Radiochemotherapy (irradiation plus gemcitabine) was started in June 2020 due to progression of the pancreatic lesion. At this time point the laboratory coagulation data including prothrombin time (PT) and activated partial thromboplastin time (APTT) were within the normal range. Three

¹Department of Gastroenterology, Nagahama Red Cross Hospital, Japan, ²Department of Medicine, Shiga University of Medical Science, Japan and ³Department of Clinical Laboratory Medicine, Nagahama Red Cross Hospital, Japan

Received: February 28, 2021; Accepted: April 20, 2021; Advance Publication by J-STAGE: June 12, 2021

Correspondence to Dr. Osamu Inatomi, osam@belle.shiga-med.ac.jp

Table. Laboratory Data at the Time of Onset.

CBC		Coagulation	
WBC	4,400 / μ L	PT	60.9 s
RBC	244 10^4 / μ L	PT activity	7 %
Hb	8.2 g/dL	PT(INR)	6.2
Hct	26.3 %	APTT	97.3 s
Plt	25.9 10^4 / μ L	Fibrinogen	365 mg/dL
Biochemistry		FDP	4.3 μ g/mL
AST	25 U/L	D-dimer	1.0 μ g/mL
ALT	14 U/L	Coagulation factor assay	
γ -GTP	564 U/L	Factor II activity	49 %
LDH	224 U/L	Factor V activity	<3 %
BUN	14.4 mg/dL	Factor VII activity	138 %
Cr	0.64 mg/dL	Factor VIII activity	93 %
Na	137.8 mEq/L	Factor IX activity	63 %
K	4.02 mEq/L	Factor X activity	58 %
Cl	101.5 mEq/L	Factor XI activity	74 %
Tumor marker		Factor XII activity	97 %
PIVKA-II	19 mAU/mL	Factor V inhibitor	1.7 BU/mL
		Factor VIII inhibitor	Negative
		Factor IX inhibitor	Negative
		Immuno-serological findings	
		Anti-cardiolipin IgG	<8 U/mL
		Lupus AC (dRVVT)	Not determined

WBC: white blood cells, RBC: red blood cells, Hb: hemoglobin, Hct: hematocrit, Pt: platelets, AST: aspartate-aminotransferase, ALT: alanine-aminotransferase, γ -GTP: γ -glutamyl transpeptidase, LDH: lactate dehydrogenase, BUN: blood urea nitrogen, Cr: creatinine, PIVKA-II: protein induced by vitamin K absence-II, PT: prothrombin time, PT(INR): prothrombin time international normalized ratio, APTT: activated partial thromboplastin time, FDP: fibrin/fibrinogen degradation products, Lupus AC: lupus anti-coagulant, dRVVT: diluted Russell's viper venom time

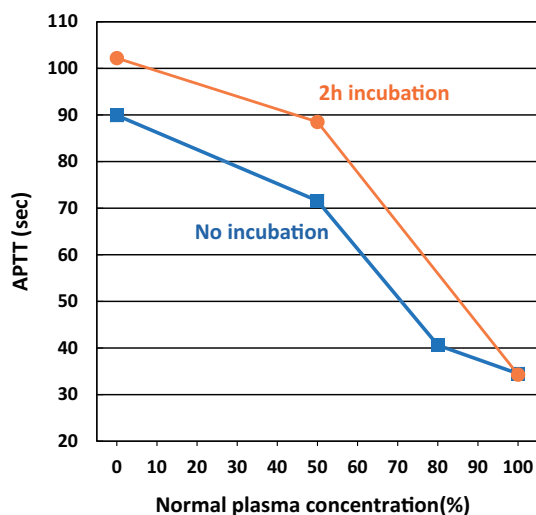


Figure. The cross-mixing test of the patient. The cross-mixing test consists of an immediate reaction that measures the coagulation time immediately after mixing normal and patient plasma, and a delayed reaction that measures the coagulation time after incubation at 37°C for 2 hours after mixing (4).

days after starting radiochemotherapy, multiple purpuras suddenly appeared on her bilateral upper limbs and a blood coagulation test revealed marked abnormalities such as PT

60.9 seconds, PT activity 7%, PT-INR 6.2 and APTT 97.3 seconds and slightly reduced activities of factors II, IX, and X (Table). Diluted Russell's viper venom time (dRVVT) for the detection of lupus anticoagulants was markedly prolonged (over 150 second, normal 30 to 40 second) and thus the results were inconclusive. Based on the possibility of vitamin K deficiency associated with biliary drainage, menatetrenone 20 mg was intravenously administered but the coagulation data did not improve. After the stocking of plasma samples for further investigation, the infusion of fresh frozen plasma was started to replace coagulation factors. Although a total of 18 units (2,160 mL) of fresh frozen plasma were administered, the coagulation data did not improve (PT activity 9% at this point). A cross-mixing test of APTT using a stocked plasma sample was performed to search for the cause of the abnormal coagulation. The cross-mixing test consists of an immediate reaction that measures the coagulation time immediately after mixing normal and patient plasma, and a delayed reaction that measures the coagulation time after incubation at 37°C for 2 hours after mixing (4). As shown in Figure, both the immediate and delayed types were convex upward and a more remarkable change was observed in the delayed type mixing test, suggesting the presence of coagulation factor inhibitors. As shown in Table, the FV activity was markedly reduced to

less than 3%, and the FV inhibitor was positive (1.7 B.U./mL). The FVIII and FIX inhibitors and lupus anticoagulant were negative. These data led to the diagnosis of acquired FV inhibitor. No bleeding tendency was observed other than purpuras on the bilateral upper limbs, but to avoid any dangerous bleeding in organs, the oral administration of prednisolone 30 mg/day (0.5 mg/kg) was started. After 7 days, the PT activity improved to 92% and APTT to 25.0 seconds. At this point, FV inhibitor was no longer detected and the FV activity improved to 114.4%. After the administration of 30 mg/day for 3 weeks, the dose of prednisolone was reduced by 5 mg/day every week. Blood tests showed no recurrence of abnormal coagulation during tapering and after the cessation of prednisolone.

Discussion

FV inhibitors are reported to affect 0.09 to 0.29 per million people per year (1). Although it is a rare pathologic situation, it is the second-most common coagulation factor inhibitor long with antibodies to von Willebrand factor, following factor VIII inhibitors (5). There are various clinical symptoms, from asymptomatic with only abnormal laboratory values to those with fatal bleeding. According to a report by Franchini et al. (1), bleeding symptoms were observed in 81%, and mucosal bleeding in the digestive tract, urinary organs, bronchi, etc. were the most common bleeding sites in 62%. On the contrary, there are multiple case reports of thrombosis (1, 6). This is considered to be because FV functions not only as a coagulation factor but also as a cofactor of protein C which inactivates the activated factor VIII (7).

Historically, the cause of the onset of acquired FV inhibitors is considered to be the generation of cross-reacting antibodies against bovine thrombin used for hemostasis in surgical treatment (1). However, bovine products are no longer used due to the advent of human recombinant thrombin and there has been a concomitant decrease in FV inhibitors arising in this setting. In this case, the patient had no history of surgical treatment with bovine thrombin. Franchini et al. reported that the causes of FV inhibitor onset include malignant tumors (22%), autoimmune diseases (10%), antibiotic use (42%), surgical procedures (31%), infectious diseases (31%) and a mixture of these factors (23%) (1). Of these, the most commonly associated condition was the use of antibiotics, such as β -lactams, aminoglycosides (especially streptomycin), cephalosporins, tetracyclines and fluoroquinolones (especially ciprofloxacin) (1). It has also been reported that the prognosis is relatively good when antibiotics are the cause. In this case, there were multiple triggers for the generation of FV inhibitors such as pancreatic cancer, cholangitis and antibiotic (β -lactams) use, and it is therefore difficult to identify which was the causative factor. In any event, since there are case reports of alveolar hemorrhage and fatal cases of cerebral hemorrhage, early diagnosis and treatment are desirable even if antibiotics are considered to

be the cause.

This patient showed a moderate reduction of other factor activities such as factor II (49%), IX (63%), X (58%) and XI (74%). The coagulation factor activity is generally measured by APTT-based (VIII, IX, XI, and XII) or PT-based (II, V, VII, and X) clotting assays, using a target coagulation factor-deficient plasma (8, 9). The activity of target coagulation factor is determined by what extent a sample plasma corrects the prolonged coagulation time of a target factor-deficient plasma in an APTT (or PT)-based assay (8, 9). Nakata et al. described that high FV inhibitor in the patient's plasma reacts with FV in a target factor-deficient plasma, leading to a pseudo-reduction of other coagulation factor activity (8). In this patient a moderate reduction of factor II, IX, X and XI activity can be explained by the same mechanism, and this is supported by a negative result of factor IX inhibitor.

Factor VII is one of vitamin K-dependent coagulation factors and its half-life has been reported to be 3-5 hours (10). Since laboratory data indicated a normal activity of factor VII (Table), we should have noticed that there is no vitamin K deficiency despite slight reduction of factors II, IX and X activities.

Treatment for acquired FV inhibitors is divided into controlling bleeding and eradicating the inhibitor, although observation may also be appropriate in some asymptomatic patients. Bleeding in patients with FV inhibitors is hard to control, since FV inhibitors are difficult to bypass with currently available coagulation factor concentrates. Since 80% of FV is present in plasma and 20% is present in the α -granules of platelets (11, 12), platelet transfusion is considered to be particularly effective and its success rate has been reported to range from 35% to 71% (12). On the other hand, immunosuppression may be required to eradicate the inhibitor. Immunosuppressive regimens with corticosteroids alone or in combination with cyclophosphamide or other immunosuppressants have been used to suppress autoantibody production. Corticosteroids are considered to be the first choice for immunosuppressive therapy (1, 12), and the introduction of other medications such as cyclophosphamide, rituximab, plasma exchange, intravenous immunoglobulin treatment may also be considered in corticosteroid-resistant patients (13, 14). In this case, we introduced oral prednisolone therapy despite the absence of any serious bleeding symptoms, since she was a cancer-suffering patient with a high risk of worsening general condition. The oral administration of prednisolone 30 mg (0.5 mg/kg)/day induced a rapid normalization of FV activity and coagulation data with disappearance of the FV inhibitor within 7 days. However, previous studies reported that FV inhibitor spontaneously disappears in approximately half of all cases and that the laboratory data tend to normalize within a couple of weeks (15, 16). Therefore, the possibility of a spontaneous disappearance of FV inhibitor could not be ruled out in this case.

We herein presented a case of FV inhibitor that showed a

rapid response to oral prednisolone therapy. The early recognition of FV inhibitor and the initiation of appropriate therapy may be important for improving the prognosis of this rare disorder.

The authors state that they have no Conflict of Interest (COI).

References

1. Franchini M, Lippi G. Acquired factor V inhibitors: a systematic review. *J Thromb Thrombolysis* **31**: 449-457, 2011.
2. Olson NJ, Robert D, Hedayat AA, Liu X, Ornstein DL. Fatal hemorrhage due to a spontaneous factor V inhibitor with lupus anticoagulant properties. *Blood Coagul Fibrinolysis* **28**: 407-410, 2017.
3. Olson NJ, Ornstein DL. Factor V inhibitors: a diagnostic and therapeutic challenge. *Arch Pathol Lab Med* **141**: 1728-1731, 2017.
4. Ashizawa M, et al. Acquired factor V inhibitor associated with life-threatening bleeding and a mixing test result that indicated coagulation factor deficiency. *Hematology* **18**: 300-304, 2013.
5. Franchini M, Lippi G, Favaloro EJ. Acquired inhibitors of coagulation factors: part II. *Semin Thromb Hemost* **38**: 447-453, 2012.
6. Ogawa H, Souri M, Kanouchi K, et al. A high titer of acquired factor V inhibitor in a hemodialysis patient who developed arterial thrombosis. *Int J Hematol* **109**: 214-220, 2019.
7. Shen L, Dahlback B. Factor V and protein S as synergistic cofactors to activated protein C in degradation of factor VIIIa. *J Biol Chem* **269**: 18735-18738, 1994.
8. Nakata K, Ueda S, Matsunaga H, et al. High titer of acquired factor V inhibitor presenting with a pseudo-deficiency of multiple coagulation factors. *Intern Med* **57**: 393-397, 2018.
9. Potgieter JJ, Damgaard M, Hillarp A. One-stage vs. chromogenic assays in haemophilia A. *Eur J Haematol* **94** (Suppl 77): 38-44, 2015.
10. Mathijssen NC, Masereeuw R, Holme PA, et al. Increased volume of distribution for recombinant activated factor VII and longer plasma-derived factor VII half-life may explain their long lasting prophylactic effect. *Thromb Res* **132**: 256-262, 2013.
11. Huang JN, Koerper MA. Factor V deficiency: a concise review. *Haemophilia* **14**: 1164-1169, 2008.
12. Ang AL, Kuperan P, Ng CH, Ng HJ. Acquired factor V inhibitor. A problem-based systematic review. *Thromb Haemost* **101**: 852-859, 2009.
13. de Raucourt E, Barbier C, Sinda P, Dib M, Peltier JY, Ternisien C. High-dose intravenous immunoglobulin treatment in two patients with acquired factor V inhibitors. *Am J Hematol* **74**: 187-190, 2003.
14. Hirai D, Yamashita Y, Masunaga N, et al. Acquired factor V inhibitor. *Intern Med* **55**: 3039-3042, 2016.
15. Kadohira Y, Yamada S, Hayashi T, Morishita E, Asakura H, Ichinose A. A discrepancy between prothrombin time and normo test (hepaplantin test) results is useful for diagnosis of acquired factor V inhibitors. *Int J Hematol* **108**: 145-150, 2018.
16. Yamada S, Asakura H. Acquired factor V inhibitor. *Rinsho Ketsueki* **61**: 791-798, 2020 (in Japanese).

The Internal Medicine is an Open Access journal distributed under the Creative Commons Attribution-NonCommercial-NoDerivatives 4.0 International License. To view the details of this license, please visit (<https://creativecommons.org/licenses/by-nc-nd/4.0/>).