

Received: 2021.01.09

Accepted: 2021.05.19

Available online: 2021.05.26

Published: 2021.07.05

Long-Term Prostate-Specific Antigen Response on a Low-Dose Cabazitaxel Regimen for Metastatic Castration-Resistant Prostate Cancer: A Case Report

Authors' Contribution:

Study Design A
Data Collection B
Statistical Analysis C
Data Interpretation D
Manuscript Preparation E
Literature Search F
Funds Collection G

ABCDEF **Shigehisa Kubota**
ADE **Susumu Kageyama**
CF **Masayuki Nagasawa**
BC **Akinori Wada**
BD **Ryo Ikari**
DF **Keiji Tomita**
ABF **Tetsuya Yoshida**
ADF **Mitsuhiro Narita**
ADE **Akihiro Kawauchi**

Department of Urology, Shiga University of Medical Science, Otsu, Shiga, Japan

Corresponding Author: Susumu Kageyama, e-mail: kageyama@belle.shiga-med.ac.jp

Conflict of interest: None declared


Patient: Male, 71-year-old
Final Diagnosis: Castration-resistant prostate cancer
Symptoms: None
Medication: —
Clinical Procedure: Chemotherapy
Specialty: Urology

Objective: Unusual clinical course
Background: Cabazitaxel is a second-generation taxane approved for patients with metastatic castration-resistant prostate cancer (CRPC). Although cabazitaxel improves overall survival when used following docetaxel chemotherapy, duration of the clinical response is relatively short, and few patients achieve a long-term response.

Case Report: A 71-year-old man with prostate adenocarcinoma with an initial prostate-specific antigen (PSA) level of 4956 ng/ml, Gleason score 4+5 and cTxNOM1b was referred to our department for treatment. Several therapeutic approaches, including androgen deprivation therapy, with a combination of bicalutamide and a luteinizing hormone-releasing hormone analogue, and 4 sequential hormonal therapies including flutamide, estramustine, enzalutamide, and abiraterone, all failed to prevent disease progression. Subsequently, after 5 cycles of docetaxel chemotherapy were also ineffective, cabazitaxel chemotherapy at a dose of 20 mg/m² together with prednisone and pegfilgrastim was initiated. The patient developed grade 4 thrombocytopenia during the first 4 cycles, and the dosage of cabazitaxel had to be tapered to 12.5 mg/m² by the fifth cycle. In subsequent cycles, the treatment was continued without grade 4 thrombocytopenia or any other toxicities ≥grade 3. The patient achieved a long-term clinical response over 4 years and his PSA level continued to decrease, from 29.8 ng/ml at treatment initiation to a nadir of 2.0 ng/ml after the 60th cycle.

Conclusions: The present case is a rare example of a sustained response to low-dose cabazitaxel, and suggests its potential as a treatment option for metastatic CRPC patients. In our patient, this approach achieved a good clinical response with manageable toxicity over the long term.

Keywords: Antineoplastic Agents • Drug-Related Side Effects and Adverse Reactions • Prostatic Neoplasms, Castration-Resistant

Full-text PDF: <https://www.amjcaserep.com/abstract/index/idArt/930989>

1504



—



2



19



Background

Prostate cancer is the most common malignancy in men, with an estimated 174 650 new cases and 31 620 deaths in the United States in 2019 [1]. Currently, 10-20% of patients develop castration-resistant prostate cancer (CRPC) within 5 years of starting androgen deprivation therapy [2]. CRPC has a poor prognosis and patients have an impaired quality of life. Depending on the extent of disease progression and severity of symptoms, life expectancy from the time of the development of castration resistance is 9-36 months [3]. Over the last decade, docetaxel-based chemotherapy has become the mainstay option for the treatment of CRPC. More recently, several new therapeutic agents have been approved, including the androgen signaling inhibitors enzalutamide and abiraterone, the radionuclide radium-223, and the new taxane cabazitaxel.

The latter is a novel semisynthetic anti-microtubule agent derived from taxanes, approved by the U.S. Food and Drug Administration (FDA) for use as second-line chemotherapy after docetaxel for metastatic CRPC, based on the results of the phase 3 TROPIC study [4]. In that study, cabazitaxel significantly increased the prostate-specific antigen (PSA) response rate and improved overall survival (OS) by 2.4 months (15.1 vs 12.7 months, $P < 0.0001$) compared with mitoxantrone [4]. In Japan, cabazitaxel was approved in 2014 following a phase 1 study, which documented that its pharmacokinetics and safety profile in Japanese patients was consistent with previous studies in other populations [5,6]. The introduction of cabazitaxel into clinical practice was expected to provide clinical benefit independent of any prior treatment regimens including androgen receptor targeted therapies or docetaxel [7,8]. However, cabazitaxel treatment-related toxicity is a major limitation for delivering an effective dose to some patients, and this can lead to a negative impact on clinical outcomes. Furthermore, although a beneficial effect on survival from extending the period of cabazitaxel treatment has been suggested, the duration of response is relatively short. Only a few patients have thus far been reported to have achieved long-term responses. Here, we report an unusual clinical case of metastatic CRPC in which a long-term clinical response to cabazitaxel was achieved, beyond 60 cycles, using a dose reduced to 12.5 mg/m² to manage severe thrombocytopenia.

Case Report

A 71-year-old man was referred to our department for the treatment of metastatic prostate cancer. He had been diagnosed with prostate cancer (initial PSA level of 4956 ng/ml, Gleason score 4+5, cTxNOM1b) at another institution 1 year before. Bone imaging revealed multiple metastases (Figure 1A), although no nodal or visceral metastasis was observed by

computed tomography at the time of diagnosis. The patient was treated with a combination of bicalutamide and a luteinizing hormone-releasing hormone (LH-RH) analogue, but developed CRPC after 30 months. Over the next 5 years, he received 4 hormonal therapies, including flutamide, estramustine, enzalutamide, and abiraterone, but his PSA level continued to increase. Docetaxel chemotherapy was initiated at a dose of 70 mg/m² intravenously every 3 weeks together with a bone-modifying agent, denosumab (120 mg) every 4 weeks. This treatment was well tolerated, but the PSA level continued to rise, from 8.3 ng/ml at the beginning of treatment to 29.8 ng/ml after 5 cycles of docetaxel therapy. At the age of 78 years, the patient was started on cabazitaxel beginning with 20 mg/m² every 3 weeks together with prednisone and pegfilgrastim. During the first cycle, grade 3 neutropenia and grade 4 thrombocytopenia occurred (graded according to the Common Terminology Criteria for Adverse Events [CTCAE] version 4.0 [9]). Therefore, cabazitaxel was reduced to 17.5 mg/m² in the second and third cycles, with grade ≥ 3 neutropenia no longer occurring, but grade 4 thrombocytopenia still present. Thus, for the third cycle, platelet transfusion was performed with platelet counts of 12 000/ μ l. For the fourth cycle, the dose of cabazitaxel was reduced to 15 mg/m², but platelet transfusion was still required to compensate for the grade 4 thrombocytopenia. After the fourth cycle, the PSA level decreased to 9.9 ng/ml and there was no radiological progression. The patient had no symptoms of non-hematological toxicity due to chemotherapy. Hence, we decided to reduce the dose of cabazitaxel and continue until progression, with the fifth cycle using a dose of 12.5 mg/m². In the subsequent cycles, the treatment was continued, and there was no recurrence of grade 4 thrombocytopenia or any other toxicities \geq grade 3. There was a delayed platelet recovery at the 18th cycle, and treatment was continued every 4 weeks at the same dose from the 19th cycle. Bone scintigraphy showed the occurrence of jaw osteonecrosis after the 26th cycle, so denosumab was discontinued until treatment for this was complete (Figure 1B). After the 52nd cycle, abnormal uptake was seen in the right femoral head and right sixth rib (Figure 1C). Further examination by MRI revealed idiopathic femoral head necrosis and traumatic rib injury without any findings of metastatic bone tumors. Nonetheless, cabazitaxel therapy was continued without evidence of radiological progression, and the PSA level gradually decreased to a nadir at 2.0 ng/ml at the end of the 60th cycle (Figure 2). Fifty-four months from the initiation of cabazitaxel, the patient continues to receive cabazitaxel therapy with uneventful adverse effects.

Discussion

Based on the results of the TROPIC trial demonstrating that 25 mg/m² of cabazitaxel improved OS, this drug is now widely used

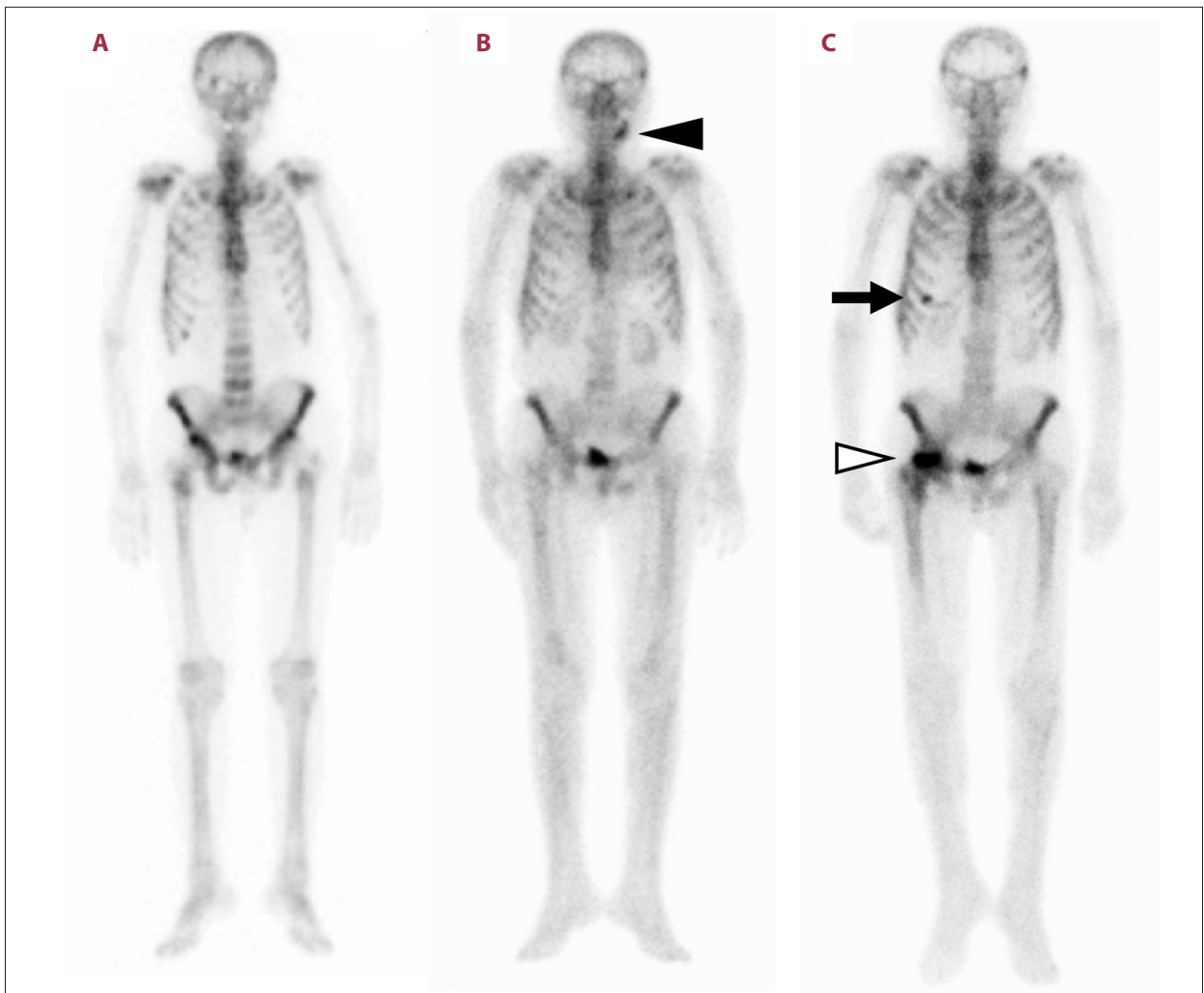


Figure 1. Status of bone metastasis by scintigraphy. (A) Multiple metastases to ribs, vertebrae and pelvic bone at the time of prostate cancer diagnosis. (B) Jaw osteonecrosis (black arrowhead) induced by denosumab occurring after the 26th cycle of cabazitaxel. (C) Abnormal uptake in the right femoral head (white arrowhead) and right sixth rib (black arrow) caused by idiopathic femoral head necrosis and traumatic rib injury after the 52nd cycle of cabazitaxel.

for metastatic CRPC after failure of treatment with docetaxel [4]. However, severe adverse events (AEs) are frequently reported, and some patients must discontinue chemotherapy or experience decreased activities of daily living on continuation. Subsequently, the PROCELICA trial determined the non-inferiority for OS of a reduced-dose cabazitaxel regimen (20 mg/m² rather than the standard 25 mg/m²), which resulted in an improved safety profile [4]. On this basis, the U.S. FDA approved 20 mg/m² of cabazitaxel as the recommended initial dosage with additional dose reduction to 15 mg/m² for the management of AEs [10].

In the present case, the starting dose of cabazitaxel was set at 20 mg/m² because of the patient's age and history of heavy pre-treatment for CRPC, but further dose reduction was required due to severe thrombocytopenia. Even with dose reduction to 15 mg/m², grade 4 thrombocytopenia still occurred, and so the

dose of cabazitaxel was further reduced to 12.5 mg/m². This finally resulted in thrombocytopenia becoming manageable. The frequency of thrombocytopenia \geq grade 3 on cabazitaxel chemotherapy is reported as 4-6.8% [4,6,11,12]. In Japanese patients in a real-world setting, this was the third most common reason leading to discontinuation or dose reduction following neutropenia [12]. These AEs associated with myelosuppression, including neutropenia and thrombocytopenia, can be managed by additional dose reduction [11]. However, no information on the oncological outcome of cabazitaxel at a dose of <20 mg/m² had been reported. Previously, outcomes, including the rate and duration of the PSA response, on a reduced-dose regimen were reported to be worse than on a standard-dose regimen [11,12]. Despite the possibility that, as mentioned above, the therapeutic effect might be reduced at a lower dose, we were concerned about the risk of recurrence

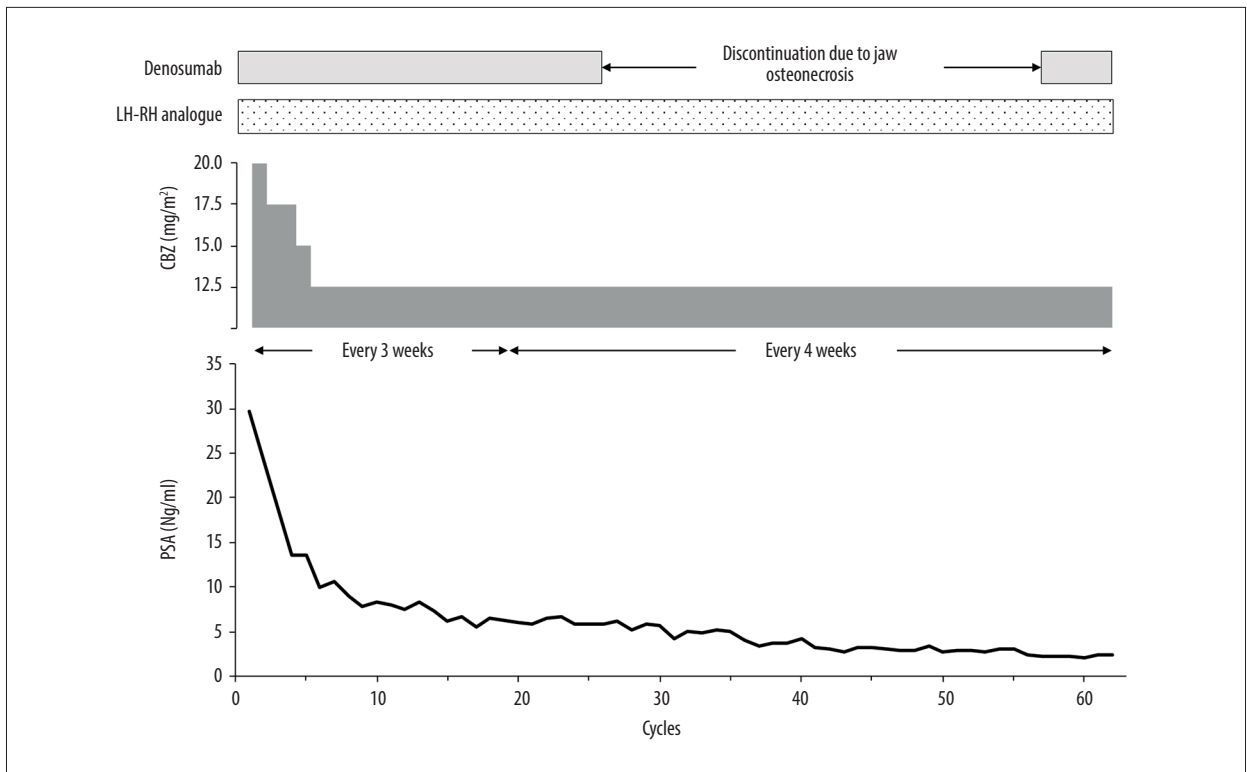


Figure 2. Clinical course after initiation of cabazitaxel chemotherapy. LH-RH – luteinizing hormone-releasing hormone; CBZ – cabazitaxel; PSA – prostate-specific antigen.

and rapid tumor regrowth if we discontinued cabazitaxel altogether [13]. We therefore decided to continue cabazitaxel treatment with an additional dose reduction.

Surprisingly, the PSA level in the present case continued to decrease despite reducing the relative dose intensity of cabazitaxel to less than 50%, reaching a nadir at the 60th cycle; thus, there was a 93.3% PSA reduction from baseline at 51 months. Furthermore, during the cabazitaxel treatment, no symptoms due to non-hematological AEs or disease progression were observed. Previously, some cases responding to ≥ 20 mg/m² of cabazitaxel beyond 20 cycles have been reported [14-16], but none had been continued beyond 30 cycles due to toxicities or disease progression. To the best of our knowledge, the present patient is the first reported to have achieved a long-term response beyond 30 cycles despite receiving a dose of < 20 mg/m². Although the mechanisms responsible for the long-term response and severe thrombocytopenia in our patient are unknown, the pharmacokinetics of cabazitaxel may be relevant. Cabazitaxel is a substrate of the transmembrane transporters P-glycoprotein (encoded by the gene *ABCB1*), OATP1B1 (*SLCO1B1*) and OATP1B3 (*SLCO1B3*) and is mainly metabolized by isoenzymes CYP3A4/5 and to a lesser extent by CYP2C8 in the liver [17-19]. Some single-nucleotide polymorphisms in these genes are known to affect the pharmacokinetics of cabazitaxel and are associated with

the incidence of grade 3-4 toxicity, although their impact on therapeutic efficacy for CRPC has not been established [19]. In the present case, no drugs affecting the pharmacokinetics of cabazitaxel, such as inhibitors of CYP3A or OATP1B, were administered during treatment. Although pharmacokinetic studies were not undertaken in the present case, we anticipate that further studies will elucidate the mechanisms underlying interpatient variability of efficacy and toxicity of cabazitaxel.

Conclusions

The present case showed long-term clinical benefits from extended cabazitaxel therapy at a very low dose without severe toxicity or impaired quality of life. Severe AEs are a serious problem that commonly interferes with the continuation of cabazitaxel therapy, but can be managed by dose reduction.

Department and Institution Where Work Was Done

Department of Urology, Shiga University of Medical Science, Otsu, Shiga, Japan.

Conflicts of Interest

None.

References:

1. Siegel RL, Miller KD, Jemal A. Cancer statistics, 2019. *Cancer J Clin*. 2019;69:7-34
2. Kirby M, Hirst C, Crawford ED. Characterising the castration-resistant prostate cancer population: A systematic review. *Int J Clin Pract*. 2011;65:1180-92
3. Heindenreich A, Bastian PL, Bellmunt J, et al. EAU guidelines on prostate cancer. Part II: Treatment of advanced, relapsing, and castration-resistant prostate cancer. *Eur Urol*. 2014;65:467-79
4. De Bono JS, Oudard S, Ozguroglu M, et al. Prednisone plus cabazitaxel or mitoxantrone for metastatic castration-resistant prostate cancer progressing after docetaxel treatment: A randomised pen-label trial. *Lancet*. 2010;376:1147-54
5. Mukai H, Takahashi S, Nozawa M, et al. Phase I dose-escalation and pharmacokinetic study (TED 11576) of cabazitaxel in Japanese patients with castration-resistant prostate cancer. *Cancer Chemother Pharmacol*. 2014;73:703-10
6. Nozawa M, Mukai H, Takahashi S, et al. Japanese phase I study of cabazitaxel in metastatic castration-resistant prostate cancer. *Int J Clin Oncol*. 2015;20:1026-34
7. Van Soest RJ, Nieuweboer AJM, De Morree ES, et al. The influence of prior novel androgen receptor targeted therapy on the efficacy of cabazitaxel in men with metastatic castration-resistant prostate cancer. *Eur J Cancer*. 2015;51:2562-69
8. Kosaka T, Hongo H, Watanabe K, et al. No significant impact of patient age and prior treatment profile with docetaxel on the efficacy of cabazitaxel in patient with castration-resistant prostate cancer. *Cancer Chemother Pharmacol*. 2018;82:1061-66
9. U.S. Department of Health and Human Services, National Institutes of Health, National Cancer Institute. Common Terminology Criteria for Adverse Events (CTCAE) Version 4.0. 2009. https://ctep.cancer.gov/protocoldevelopment/electronic_applications/ctc.htm#ctc_40
10. Center for Drug Evaluation and Research: NDA 20-1023 SUPPLEMENT APPROVAL FULFILLMENT OF POSTMARKETING REQUIREMENTS: Cabazitaxel. Updated 2017. https://www.accessdata.fda.gov/drugsatfda_docs/label/2017/201023s019lbl.pdf
11. Eisenberger M, Hardy-Bessard AC, Kim CS, et al. Phase III STUDY COMPARING A REDUCED DOSE OF Cabazitaxel (20 mg/m²) and the currently approved dose (25 mg/m²) in postdocetaxel patients with metastatic castration-resistant prostate cancer-PROSELICA. *J Clin Oncol*. 2017;35:3198-206
12. Suzuki K, Matsubara N, Kazama H, et al. Safety and efficacy of cabazitaxel in 660 patients with metastatic castration-resistant prostate cancer in real-world settings: Results of a Japanese post-marketing surveillance study. *Jpn J Clin Oncol*. 2019;49:1157-68
13. Di Lorenzo G, Buonerba C, De Placido S. Rapidly progressive disease in a castration-resistant prostate cancer patient after cabazitaxel discontinuation. *Anticancer Drugs*. 2015;26:236-39
14. Pal SK, Stein CA. Prolonged therapy with cabazitaxel in an octogenarian with metastatic castration-resistant prostate cancer. *Clin Genitourin Cancer*. 2012;10:274-76
15. Noronha V, Joshi A, Prabhaskar K. Beyond ten cycles of cabazitaxel for castration-resistant prostate cancer. *Indian J Cancer*. 2014;51:363-65
16. Atag E, Semiz HS, Kazaz SH, et al. Response to cabazitaxel beyond 20 cycles in a patient with penile metastasis of prostate cancer: A case report. *Urol J*. 2017;14:2985-88
17. Pean E, Demolis P, Moreau A, et al. The European medicines agency review of cabazitaxel (Jevtana®) for the treatment of hormone-refractory metastatic prostate cancer: Summary of the scientific assessment of the committee for medical products for human use. *Oncologist*. 2012;17:543-49
18. De Morree ES, Bottcher R, van Soest RV, et al. Loss of SCL10B3 drives taxane resistance in prostate cancer. *Br J Cancer*. 2016;115:674-81
19. Belderbos BPS, With M, Singh RK, et al. The influence of single-nucleotide polymorphisms on overall survival and toxicity in cabazitaxel-treated patients with metastatic castration-resistant prostate cancer. *Cancer Chemother Pharmacol*. 2020;85:547-53