

# Delayed Cerebrospinal Fluid Leak after Watertight Dural Closure with a Polyethylene Glycol Hydrogel Dural Sealant in Posterior Fossa Surgery: Case Report

Junya JITO,<sup>1</sup> Naoki NITTA,<sup>1</sup> and Kazuhiko NOZAKI<sup>1</sup>

<sup>1</sup>Department of Neurosurgery, Shiga University of Medical Science, Otsu, Shiga

## Abstract

A polyethylene glycol (PEG) hydrogel sealant recently has been approved as an adjunct to sutured dural closure in Japan. We treated consecutive six patients with PEG hydrogel sealant in posterior fossa operation. Three of six cases suffered delayed cerebrospinal fluid (CSF) leak after watertight dural closure with the PEG hydrogel sealant, although there was no leak case which was treated with fibrin glue, before 2 years until the adoption of the new material. These patients underwent posterior fossa craniotomy and discharged without remarkable CSF leak. The pseudomeningocele under the occipital wound caused the CSF leak occur from 5th to 7th week postoperatively. All CSF leak cases needed surgical repair. At the repair, the PEG hydrogel was liquefied and almost absorbed. A fistula on the closure line and a dead space after the absorption of the PEG hydrogel was observed. When the absorbable PEG hydrogel sealant plugs in small gaps of sutured dura, its properties to prevent adhesion might suppress healing process of dural closure, so that CSF could leak through the gaps and collect as a pseudomeningocele in the dead space after absorption of the PEG hydrogel. In posterior fossa surgery a PEG hydrogel sealant should be applied when dural edges are closed tightly without any gaps.

Key words: delayed cerebrospinal fluid leak, polyethylene glycol hydrogel dural sealant, posterior fossa surgery

## Introduction

Cerebrospinal fluid (CSF) leak is a potentially dangerous complication after posterior fossa surgery. Although the surgical technique and adjuvant procedure for dural closure has been progressed, postoperative CSF leaks, particularly in posterior fossa cases, have been observed as high as 17%.<sup>1–7)</sup>

After the approval of the polyethylene glycol (PEG) hydrogel sealant in 2005 by the US FDA (<http://www.fda.gov/Medical Devices/Products and Medical Procedures/Device Approvals and Clearances/Recently-Approved Devices/ucm078645.htm>), the utility and safety of PEG hydrogel sealant as an adjunct to sutured dural repair in cranial surgery, especially for posterior fossa operations, has been published in some reports.<sup>2,8–10)</sup> In January 2010, new PEG hydrogel dural sealant product (DuraSeal™ Dural Sealant System; Covidien, Tokyo) was

approved in Japan by the Ministry of Health, Labour, and Welfare (<http://www.mhlw.go.jp/english/index.html>) as an adjunct to sutured dural repair in cranial surgery. The application of this material to the closed dural edges was reported to provide a safe and effective watertight closure during cranial surgery, and to be more effective in reducing incisional CSF leak after posterior fossa surgery than the application of fibrin glue only.<sup>2,9)</sup> To date, the only complication linked to the use of this material is extradural mass effect due to hydrogel expansion.<sup>11–13)</sup>

We present three cases of pseudomeningocele caused by delayed CSF leak after the application of this dural sealant to the closed dural edges, which had not been observed after the application of fibrin glue in our experiences.

We also reviewed the literatures about the PEG hydrogel sealant systemically to compare with our result, and found a high incidence of pseudomeningocele caused by delayed CSF leak after the application of this dural sealant product for posterior fossa surgery.

## Materials and Methods

We treated consecutive 6 patients with DuraSeal™ (PEG group) in posterior fossa surgery from April 2010 to September 2010. Three patients were treated by PEG hydrogel sealant only after dural closure following the regulation of the usage for the material, as the dura was closed without gap wider than 2 mm. A PEG hydrogel dural sealant was sprayed over the dura and watertight dural closure was confirmed. Other three patients were treated by the pedicle muscle flap coating over the closure line of the dura, for the repair of the fistula into the mastoid air cells, before PEG hydrogel sealing. And one of these patients was also added covering with the artificial bone for the bone defect after PEG hydrogel sealing. The fascia and skin was closed in a standard fashion in all cases. The characteristics of the PEG group patients are detailed in Table 1.

The diagnosis of CSF leak was based upon retroauricular subcutaneous symptomatic CSF collection as a pseudomeningocele on magnetic resonance imaging (MRI) or computed tomography (CT) which after two or more times of punctures of the fluid collection or after removal of the lumbar drainage.

## Result

### I. CSF leak

There was no case with intraoperative CSF leak after sutured dural repair. Three of six patients developed a pseudomeningocele as an incisional CSF leak during 8 weeks postoperatively. All CSF leaks became symptomatic between the 5th and 7th week postoperatively. There was no case of transient CSF leak, and the onset of the CSF leak was delayed after surgery. Three patients without CSF leak were treated by the pedicle muscle flap coating and covering with the artificial bone with PEG hydrogel sealing. On the other hand, three patients with delayed CSF leak were treated by only PEG hydrogel sealant after dural closure.

### II. Treatment of CSF leak

All CSF leak cases needed surgical repair. At the repair, the PEG hydrogel was nearly hydrolyzed, and the retention cavity of CSF became the dead space. Adhesion was not observed between the cavity wall and the dura mater. A fistula presented obviously in all CSF leak cases, and an outflow of the CSF was observed (Fig. 1). All patients with CSF leak were performed re-operation for repairing the fistula by watertight closure of the dura with muscle patch and sealing with the fibrin glue. Postoperatively, the lumbar drain was kept for further about 2 weeks. No recurrences of CSF leak or delayed onset meningitis were seen during a minimum follow-up of 2 months after the reoperation.

### III. Illustrative case

A 60-year-old woman was admitted with a right unruptured vertebral artery aneurysm on computed tomographic angiogram. Physical examination revealed no neurologic deficits. She underwent a clipping of the aneurysm through right suboccipital approach. Linear dural incision was performed along sigmoid sinus. Dura was primarily closed without autologous materials and an incisional gap was less than 2 mm. PEG hydrogel sealant was sprayed over the dura and watertight dural closure was confirmed. The fascia was closed in a standard fashion. Postoperatively the patient had mild hoarseness, but CT showed no pseudomeningocele as a subcutaneous fluid collection, and she was discharged 2 weeks after the operation (Fig. 2A).

Five weeks after the operation, the patient had nausea and appetite loss. There was a subcutaneous swelling around the wound. A MRI showed pseudomeningocele under the wound (Fig. 2B). Laboratory test showed hyponatremia. Although her symptoms improved after the treatment of hyponatremia, pseudomeningocele, and subcutaneous swelling around the wound recurred after the removal of the lumbar drainage. Surgical CSF fistula closure was performed. During the operation, we confirmed that the absorbable dural sealant was liquefied and absorbed.

**Table 1** The characteristics of the polyethylene glycol group

Case	Sex	Age	Disease	Approach	CSF leak	Duration	Reinforcement of the dural closure
1	F	82	Trigeminal neuralgia	Left lateral suboccipital	(-)	/	Covered with pedicle muscle flap for repairing mastoid air cells
2	F	59	VA aneurysm	Right lateral suboccipital	(+)	5 W	Only PEG hydrogel sealing
3	F	46	Meningioma, CP angle	Left lateral suboccipital	(-)	/	Covered with pedicle muscle flap for repairing mastoid air cells
4	M	20	Hemangioblastoma	Midline suboccipital	(+)	6 W	Only PEG hydrogel sealing
5	M	43	Hemifacial spasm	Left lateral suboccipital	(+)	7 W	Only PEG hydrogel sealing
6	F	49	Vestibular schwannoma	Left lateral suboccipital	(-)	/	Covered with pedicle muscle flap and artificial bone for repairing mastoid air cells

CP angle: cerebellopontine angle, F: female, M: male, PEG: polyethylene glycol, VA: ventral artery, W: weeks.

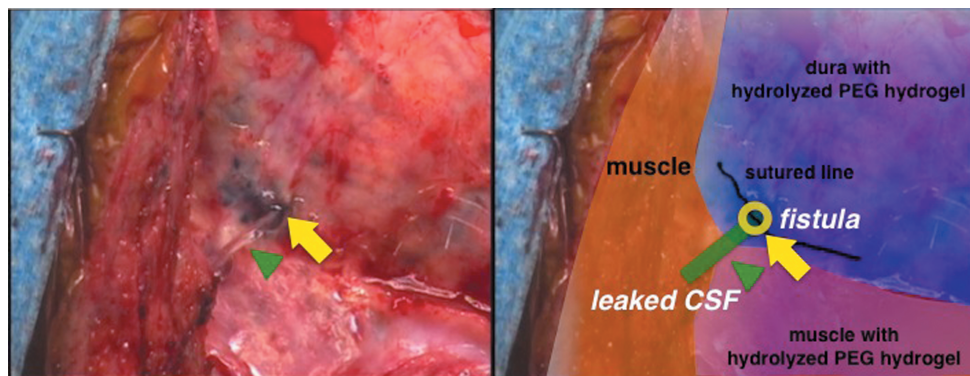


Fig. 1 Intraoperative photograph (left) and schema (right) during the surgical repair of cerebrospinal fluid (CSF) leak, showing hydrolysis almost of all the polyethylene glycol (PEG) hydrogel, no adhesion between cyst wall and the dura mater, an outflow of the CSF (arrowhead) from an obvious fistula (arrow) on the dural closure line.

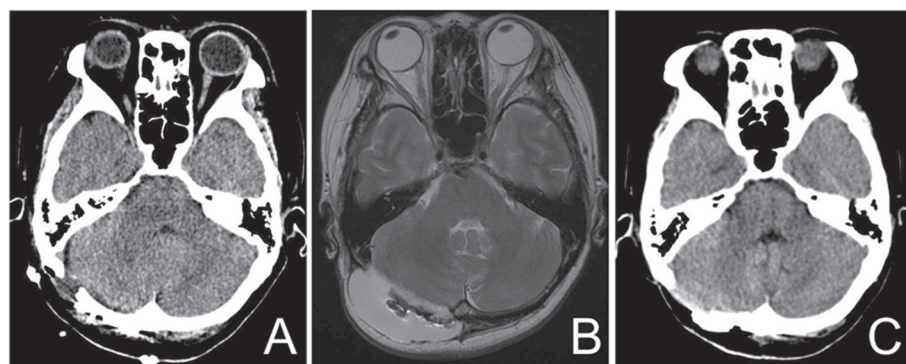


Fig. 2 A computed tomography (CT) scan of head one day after first operation (A) showing no apparent pseudomeningocele, an axial magnetic resonance imaging about 5 weeks after first operation (B) showing a pseudomeningocele under operative wound, and a CT scan 2 weeks after second operation (C) showing no pseudomeningocele.

A CSF fistula smaller than 1 mm was observed at the lower end of the dural incision scar of the previous operation. After the fistula was closed primarily with a suture string, the dura around the fistula was covered with a pedicled muscle flap. Fibrin glue was sprayed over the dura and dead space was closed meticulously. Postoperative pseudomeningocele was not observed on the CT and the patient was discharged (Fig. 2C), and she had no pseudomeningocele for 3 months.

## Discussion

After the approval of the PEG hydrogel sealant for neurosurgical applications as an adjunct to dural closure, the utility and safety in cranial surgery, especially in posterior fossa operations, has been reported. At present, five human clinical studies have been published in peer-reviewed journals on the use of PEG hydrogel sealant as a means of achieving watertight dural closure. Table 2 shows the incidence rate of the postoperative CSF leak in each published report, containing the present study. In the US DuraSeal Pivotal Trial which was the first study to estimate the utility and safety of the single usage of PEG hydrogel sealant such as the DuraSeal sealant (Confluent Surgical, Inc., Waltham, Massachusetts, USA) without autologous materials, the overall CSF leak rate with using a PEG hydrogel sealant was 4.50% (in 5 of 111 patients).<sup>2,10)</sup> Boogaarts et al. prospectively treated

46 patients with DuraSeal sealant in combination with autologous materials. They found 1 (2.17%) overt CSF leak case over a 3-month course of follow-up.<sup>8)</sup> Osbun et al. showed the first result of the multicenter, prospective randomized study for the evaluation of the efficacy of a PEG hydrogel sealant compared with common dural sealing techniques including the procedure using fibrin glue.<sup>14)</sup> They reported that the CSF leaks was similar between group treated with PEG hydrogel sealant and control group, with no statistically significant difference between the measures. In the PEG hydrogel group, the incidence of CSF leak was 0.83% (1/120). In the control group, the incidence of CSF leak was 1.71% (2/117). It has been shown that the PEG hydrogel sealant has not been inferior to the common dural sealing techniques in the multicenter, prospective randomized study.<sup>14)</sup>

Sawaya et al. used multivariate analysis to establish that major regional complications—including CSF leak—were almost six times more likely to occur in infratentorial procedures than in supratentorial procedures (odds ratio 5.84).<sup>15)</sup> Cosgrove et al. prospectively evaluated the safety and efficacy of a PEG hydrogel sealant in patients on a mix of cranial cases. The rate of the postoperative incisional CSF leakage for posterior fossa operations was 1.89% (one of 53 patients) in the same report.<sup>2)</sup> Osbun et al. showed the rate of the postoperative CSF leakage for posterior fossa operations as 2.78% (one of 36 patients) in the PEG hydrogel group, 2% (one of 50 patients) in the patients

**Table 2** The incidence of the postoperative cerebrospinal fluid leak in previous published reports

Authors	Year	Total CSF leak		CSF leak of the posterior fossa cases	
		PEG	Control*	PEG	Control*
Boogaarts et al. (2005) <sup>8)</sup>	2005	1/46 (2.17%) with autologous materials	NA	NA	NA
Cosgrove et al. (2007) <sup>2)</sup> [same as U.S. Food and Drug Administration <sup>10)</sup> ]	2007	5/111 (4.50%)	NA NA	1/53 (1.89%)	NA
Than et al. (2008) <sup>9)</sup>	2008	NA	NA	2/100 (2.00%)	10/100** (10.0%)
Weinstein et al. (2010) <sup>20)</sup>	2010	5/66 (7.58%) with nonautologous materials 3/50 (6.00%) with autologous materials	NA NA	NA NA	NA NA
Osun et al. (2012) <sup>14)</sup>	2011	1/120 (0.83%)	2/117 (1.71%)	1/36 (2.78%)	1/50 (2.00%)
Jito et al. (present study)	2013	NA	NA	3/6 (50.0%)	

\*the patients were repaired by commonly used dural sealing techniques except for use of a PEG. \*\*All cases were repaired by fibrin glue. CSF: cerebrospinal fluid, NA: not available, PEG: polyethylene glycol.

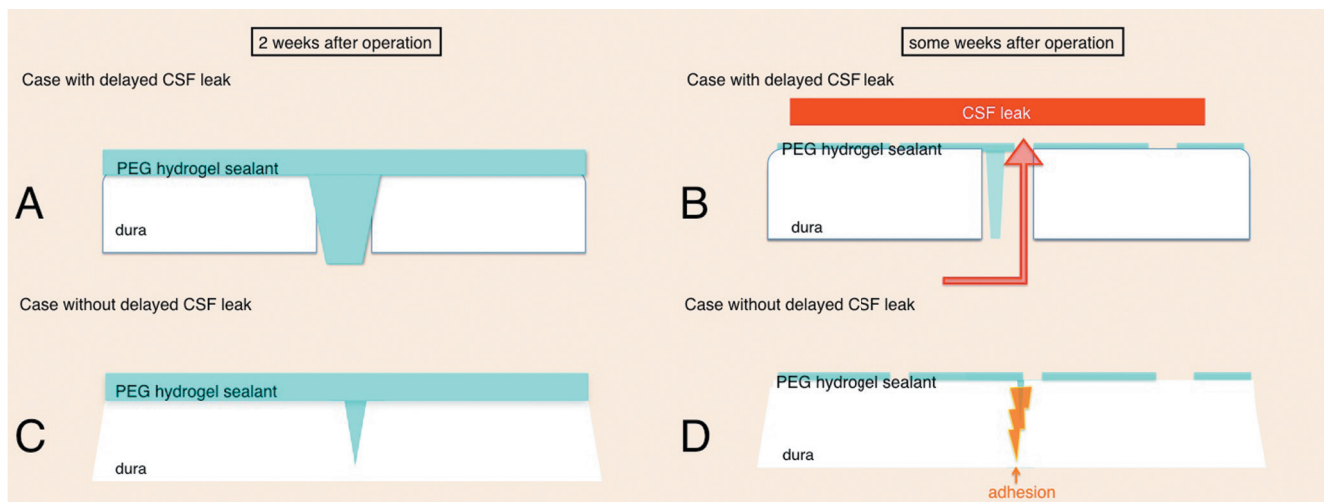
with common dural sealing techniques, respectively.<sup>14)</sup> Than et al. reported the efficacy of a PEG hydrogel sealant at preventing incisional CSF leak after posterior fossa surgery with comparison to the procedure using fibrin glue for dural closure. While 10 of 100 (10.0%) patients in whom fibrin glue was used developed an incisional CSF leak, in the PEG group, two of 100 (2%) patients developed an incisional CSF leak postoperatively. This difference was statistically significant, with a P value of 0.03.<sup>9)</sup> These results suggest that PEG hydrogel sealant is more effective against CSF leak than fibrin glue in posterior fossa surgery. In our institute, although we used to use fibrin glue for covering the watertight dural closure in posterior fossa surgery, delayed CSF leak that needed surgical intervention had not been observed for recent 2 years before the adoption of PEG hydrogel sealant. However, we experienced three cases of pseudomeningocele due to delayed CSF leak for short period after we began to use the PEG hydrogel sealant, in spite of performing operations by the same neurosurgical staffs. Our results for the incidence of CSF leak using the PEG hydrogel sealant were extremely high, beyond the range of the previously report (Table 2). This result suggests that a PEG hydrogel sealant is not necessarily superior to fibrin glue in terms of preventing CSF leak. Fibrin glue is eventually replaced by granulation tissue and scar made of connective tissue is formed.<sup>16)</sup> Thus connective tissue is presumed to fill and close between the dural edges, and between bone or myocutaneous flap and dura after the application of fibrin glue, resulting in semi-permanent watertight dural closure and prevention of getting the dead space in the operative field by the adhesion.

About the mechanism of delayed CSF leak after watertight dural closure with the PEG hydrogel sealant, the following hypotheses are suggested. First is that the PEG hydrogel sealant inhibits dural gap healing. As reported previously, the PEG hydrogel may expand and prevent

adhesion between dural edges.<sup>11,17–19)</sup> The PEG hydrogel expands at least during first two weeks.<sup>11,18)</sup> If the PEG hydrogel invades and occupies the gaps of the dural closure like putty, expanding the hydrogel causes a separation of the dural edges (Fig. 3A). The hydrogel will be gradually hydrolyzed until about 8 weeks, and breakdown products due to spontaneous hydrolysis, including the PEG molecules, will be absorbed and cleared by the kidneys (quotation from the Web site of Covidien). When the PEG hydrogel is absorbed in 4 to 8 weeks after operation, CSF may leak via the unhealed dural edges (Fig. 3B).<sup>18,19)</sup> In our cases pseudomeningoceles as an incisional CSF leak happened between the 5th and 7th week postoperatively, the period for the delayed incidence of pseudomeningoceles corresponded to the timing of the PEG hydrogel absorption. This hypothesis suggests that dural edges should touch each other and the gaps of dural closure should not be remain before using the PEG hydrogel sealant in order not to interfere with the adhesion of the dural edges (Fig. 3C, D).

Second hypothesis is that epidural expanding the PEG hydrogel separates dura and occipital bone or myocutaneous flap. In posterior fossa surgery shrinkage of dura during surgery sometimes causes flat surface after closure. If the PEG hydrogel occupies epidural space, expanding the hydrogel causes a separation between the dura and occipital bone or myocutaneous flap.<sup>11–13)</sup> And the PEG hydrogel is reported to work as adhesion inhibitor between the bone and the dura.<sup>11)</sup> This separation may induce the dead space after absorption of the PEG hydrogel between dura and bone or myocutaneous flap. If a fistula exists on the sutured dura when the PEG hydrogel breaks down into water-soluble molecules, CSF easily penetrate the PEG hydrogel and flood into epidural space through the fistula, because dura does not adhere to bone or myocutaneous flap. These may induce the formation of delayed





**Fig. 3** Schematic drawings (A–D) for the hypothetical concept of the delayed CSF leak after using the PEG hydrogel sealant. Scheme A shows the prevention of the adhesion between the dural edges due to expansion of the PEG hydrogel sealant plugged in a gap of closed dural edges about 2 weeks after operation. Scheme C shows the PEG hydrogel sealing without a small gap of closed dural edges. In both case, CSF leakage is not yet observed (A, C). Schemes B, D for some weeks after operation when the PEG hydrogel is hydrolyzed, showing no adhesion between dural edges and the obvious fistula as a remaining of the dural gap in the case with delayed CSF leak (B), and showing the complete adhesion the dural gap in the case without delayed CSF leak (D). CSF: cerebrospinal fluid, PEG: polyethylene glycol.

pseudomeningocele. The patients without CSF leak in our cases were treated by the pedicle muscle flap coating before PEG sealing or covering by the artificial bone after PEG sealing. Weinstein et al. reported the incidence of postoperative CSF leakage was 7.58% in the group treated with nonautologous materials and 6% with autologous materials.<sup>20)</sup> Both autologous and nonautologous duraplasty materials did not result in CSF leak when using with PAG hydrogel sealant. These materials might be the prevention of getting the dead space in the operative field.

## Conclusion

We reported a high incidence of delayed CSF leaks after posterior fossa surgery using a PEG hydrogel dural sealant after primary closure of dura, and considered that a PEG hydrogel dural sealant should be applied when dural edges are closed tightly without any gaps and where dura and bone forms a convex surface such as supratentorial region.

## Conflicts of Interest Disclosure

There are no conflicts of interests or financial interest that could compromise the author's scientific and medical approach to the subject and patient management.

## References

- 1) Bryce GE, Nedzelski JM, Rowed DW, Rappaport JM: Cerebrospinal fluid leaks and meningitis in acoustic neuroma surgery. *Otolaryngol Head Neck Surg* 104: 81–87, 1991
- 2) Cosgrove GR, Delashaw JB, Grotenhuis JA, Tew JM, Van Loveren H, Spetzler RF, Payner T, Rosseau G, Shaffrey ME, Hopkins LN, Byrne R, Norbash A: Safety and efficacy of a novel polyethylene glycol hydrogel sealant for watertight dural repair. *J Neurosurg* 106: 52–58, 2007
- 3) Fishman AJ, Hoffman RA, Roland JT, Lebowitz RA, Cohen NL: Cerebrospinal fluid drainage in the management of CSF leak following acoustic neuroma surgery. *Laryngoscope* 106: 1002–1004, 1996
- 4) Fishman AJ, Marrinan MS, Golfinos JG, Cohen NL, Roland JT: Prevention and management of cerebrospinal fluid leak following vestibular schwannoma surgery. *Laryngoscope* 114: 501–505, 2004
- 5) Hoffman RA: Cerebrospinal fluid leak following acoustic neuroma removal. *Laryngoscope* 104: 40–58, 1994
- 6) Nutik SL, Korol HW: Cerebrospinal fluid leak after acoustic neuroma surgery. *Surg Neurol* 43: 553–556; discussion 556–557, 1995
- 7) Samii M, Matthies C: Management of 1000 vestibular schwannomas (acoustic neuromas): surgical management and results with an emphasis on complications and how to avoid them. *Neurosurgery* 40: 11–21; discussion 21–23, 1997
- 8) Boogaarts JD, Grotenhuis JA, Bartels RH, Beems T: Use of a novel absorbable hydrogel for augmentation of dural repair: results of a preliminary clinical study. *Neurosurgery* 57: 146–151; discussion 146–151, 2005
- 9) Than KD, Baird CJ, Olivi A: Polyethylene glycol hydrogel dural sealant may reduce incisional cerebrospinal fluid leak after posterior fossa surgery. *Neurosurgery* 63(1 Suppl 1): ONS182–186; discussion ONS18–187, 2008

- 10) U.S. Food and Drug Administration Silver Spring, MD: Summary of safety and effectiveness data: DuraSeal Dural Sealant System, 2005. Available at [http://www.accessdata.fda.gov/cdrh\\_docs/pdf4/P040034b.pdf](http://www.accessdata.fda.gov/cdrh_docs/pdf4/P040034b.pdf) Accessed June 23, 2009
- 11) Blackburn SL, Smyth MD: Hydrogel-induced cervicomedullary compression after posterior fossa decompression for Chiari malformation. Case report. *J Neurosurg* 106(4 Suppl): 302–304, 2007
- 12) Mulder M, Crosier J, Dunn R: Cauda equina compression by hydrogel dural sealant after a laminotomy and discectomy: case report. *Spine (Phila Pa 1976)* 34: E144–148, 2009
- 13) Thavarajah D, De Lacy P, Hussain R, Redfern RM: Postoperative cervical cord compression induced by hydrogel (DuraSeal): a possible complication. *Spine* 35: E25–26, 2010
- 14) Osbun JW, Ellenbogen RG, Chesnut RM, Chin LS, Connolly PJ, Cosgrove GR, Delashaw JB, Golfinos JG, Greenlee JD, Haines SJ, Jallo J, Muizelaar JP, Nanda A, Shaffrey M, Shah MV, Tew JM, van Loveren HR, Weinand ME, White JA, Wilberger JE: A multicenter, single-blind, prospective randomized trial to evaluate the safety of a polyethylene glycol hydrogel (Duraseal Dural Sealant System) as a dural sealant in cranial surgery. *World Neurosurg* 78: 498–504, 2012
- 15) Sawaya R, Hammoud M, Schoppa D, Hess KR, Wu SZ, Shi WM, Wildrick DM: Neurosurgical outcomes in a modern series of 400 craniotomies for treatment of parenchymal tumors. *Neurosurgery* 42: 1044–1055; discussion 1055–1056, 1998
- 16) Kroez M, Lang W, Dickneite G: Wound healing and degradation of the fibrin sealant Beriplast P following partial liver resection in rabbits. *Wound Repair Regen* 13: 318–323, 2005
- 17) Ferland R, Mulani D, Campbell PK: Evaluation of a sprayable polyethylene glycol adhesion barrier in a porcine efficacy model. *Hum Reprod* 16: 2718–2723, 2001
- 18) Kacher DF, Frerichs K, Pettit J, Campbell PK, Meunch T, Norbash AM: DuraSeal magnetic resonance and computed tomography imaging: evaluation in a canine craniotomy model. *Neurosurgery* 58(1 Suppl): ONS140–147; discussion ONS140–147, 2006
- 19) Preul MC, Bichard WD, Spetzler RF: Toward optimal tissue sealants for neurosurgery: use of a novel hydrogel sealant in a canine durotomy repair model. *Neurosurgery* 53: 1189–1198; discussion 1198–1199, 2003
- 20) Weinstein JS, Liu KC, Delashaw JB, Burchiel KJ, van Loveren HR, Vale FL, Agazzi S, Greenberg MS, Smith DA, Tew J: The safety and effectiveness of a dural sealant system for use with nonautologous duraplasty materials. *J Neurosurg* 112: 428–433, 2010

---

Address reprint requests to: Junya Jito, MD, PhD, Department of Neurosurgery, Shiga University of Medical Science, Seta-Tsukinowa-Cho, Otsu, Shiga 520-2192, Japan.  
e-mail: xjun5@belle.shiga-med.ac.jp