

## Secondary Pulmonary Alveolar Proteinosis : An Autopsy Case of Chronic Myelogenous Leukemia with Disseminated Trichosporosis and Tuberculosis

Ryoji KUSHIMA<sup>1</sup>, Miyuki TAKADA<sup>2</sup>, Takashi MOCHIZUKI<sup>3</sup>,

Naoki ARIZONO<sup>4</sup>, Osamu KORETOU<sup>4</sup>, Yasuhiro IWAI<sup>4</sup>, and Osamu TAKEOKA<sup>4</sup>

<sup>1</sup>Department of Laboratory Medicine, <sup>2</sup>Second Department of Internal Medicine,

<sup>3</sup>Department of Dermatology & <sup>4</sup>First Department of Pathology,

Shiga University of Medical Science

An autopsy case of chronic myelogenous leukemia (CML) is reported, the lungs of which showed pulmonary alveolar proteinosis. A rare visceral mycosis, *Trichosporon beigeli* infection, and a tuberculous infection were also found. The patient, a 69-year-old man, who had been previously treated with busulfan due to a typical Ph<sup>1</sup>-positive CML, died of severe dyspnea with fever. An autopsy revealed a large number of alveoli filled with eosinophilic granular material. Histochemically, the material was the same as that of alveolar proteinosis previously described by some authors. An electron-microscopic study demonstrated numerous osmiophilic particulate components with many myelin-like figures. Furthermore, sections of lungs demonstrated some nodules of caseous necrosis with little epithelioid reaction. In the latter lesion, numerous acid-fast bacilli were demonstrated. A review of the literature disclosed 44 reported cases of alveolar proteinosis associated with hematological disorders, including 10 cases with CML and 5 cases with tuberculosis. It is concluded that the alveolar proteinosis secondary to hematological disorders is due to the accumulation of cell debris and impairment of alveolar clearance.

**Key words :** alveolar proteinosis, trichosporosis, tuberculosis, CML

### Introduction

Pulmonary alveolar proteinosis, first de-

scribed by Rosen et al.,<sup>1)</sup> is characterized by intraalveolar accumulation of large quantities of PAS (periodic acid-Schiff) positive granular lipoproteinaceous material in a patient with no under-

---

Accepted for publication November 17, 1987

九嶋亮治, 高田美雪, 望月 隆, 有菌直樹, 惟任 修, 岩井泰博, 竹岡 成

Mailing address: Shiga University of Medical Science, Otsu, Shiga, 520-21, JAPAN

lying disorders. Similar pulmonary lesions have also been reported in immunosuppressive patients with some hematological disorders<sup>2-30</sup>. Among them, 10 cases were associated with CML<sup>3,4,7,8,11,17,18,22,24,25,30</sup> and 5 cases with tuberculosis<sup>4,7,19,22</sup>. In Japan, only 4 cases of such pulmonary lesions have previously been reported<sup>13,18,29,30</sup> including 2 cases with CML<sup>13,30</sup>.

*Trichosporon beigelii* (*T. beigelii*) is a fungus which may cause a superficial infection of the hair shaft called white piedra<sup>31</sup>. Cases of systemic infection by it have been increasingly reported in recent years. Most of them were found in the immunosuppressive patients<sup>32-34</sup>.

We experienced a case of CML with infection of *T. beigelii* and acid-fast bacilli, in which pulmonary alveolar proteinosis developed. The case was studied histochemically and electron-microscopically, and the pathogenesis of pulmonary alveolar proteinosis especially associated with hematological disorders and with tuberculosis was discussed.

### Case report

A 69-year-old man was admitted to the university hospital because of increasing general malaise and epigastric dullness in September 1984. He was diagnosed as a typical Ph<sup>1</sup>-positive CML. He was treated with 1.4 mg busulfan daily from September to December 1984, and was discharged. From then to May 1985, he was in such good condition that he did not visit the hospital. He was readmitted to the hospital complaining of epigastric dullness and treated with 2 mg of busulfan daily from June to August 1985. After that, he was given 1.2 mg of busulfan daily. In October 1986, he was again admitted to the hospital because of continuous high fever (40°C) with dyspnea. There was no evidence of a blast crisis of the CML. The chest X-P had showed an interstitial fibrotic pattern during the entire clinical

course.

No mycobacterium was proven during the clinical course, in spite of repeated sputum cultures.

Venous blood was cultured for mycological study 3 days before death. Within 7 days on primary isolation media, cream colored colonies developed. The fungus was identified as *Trichosporon beigelii* by morphological and biochemical studies. Other fungi were not identified. Serological examinations showed no indication of viral infections.

The patient died of severe dyspnea with high fever on April 8, 1987.

### Subjects and Methods

All the organs at autopsy were fixed in 10% formalin solution. The tissues were embedded in paraffin and prepared for light microscopic observation. All the specimens were stained with H.E. (hematoxylin and eosin) and PAS. For the lung specimens, the following staining methods were also employed; Grocott's methenamine silver, Ziehl-Neelsen, diastase digestion + PAS, acetylation + PAS, acetylation + deacetylation + PAS, PTAH (phosphotungstic acid-hematoxylin), Azan-Mallory, Sudan III, Millon reaction, toluidine blue and alcian blue staining.

For electron-microscopical study, specimens of the lung embedded in paraffin were deparaffinized, cut in 1 mm cubes and refixed in 2.5% glutaldehyde for 2 hours and in 2% osmium tetroxide for 2 hours. Then they were dehydrated in a graded ethanol and embedded in a mixture of Spurr. Ultrathin sections were stained with aqueous uranyl acetate and lead acetate, and then observed with a Hitachi H-700 electron microscope.

## Results

### Gross findings

An autopsy was performed 2 hours after death. The emaciated body measured 170 cm in length and weighed 41 kg. The peritoneal cavity contained no excess amount of fluid. There were several enlarged mesenteric lymph nodes whose cut surfaces were gray-white in color. Each pleural cavity contained about 100 ml of fluid respectively, which was brown in color. There were no adhesions of the pleurae. Some mediastinal lymph nodes were enlarged. The heart weighed 260 g and there were petechial hemorrhages scattered on the surface of the epicardium.

The lungs were markedly swollen (800/920 g). Diffuse subpleural hemorrhage was seen. The cut surfaces were hemorrhagic and dark-red in




Fig. 1. Cat surface of the right lung, after fixation. Emphysema and interstitial thickening are seen. Many ill-defined indurations are palpable, but not visible due to diffuse hemorrhage.

color, and there were many ill-defined indurations. Emphysema and interstitial fibrosis were also found. These changes were observed in all the lobes (Fig. 1).

The liver weighed 1,400 g. The cut surface was yellow-brown in color and showed minute white lesions. The spleen was enlarged (430 g); there were minute white lesions on the cut surface. The kidneys (190/160 g) showed cloudy swelling. In the urinary bladder, a hemorrhagic polypoid lesion was seen. The bone marrow was red in color.

### Microscopic study

In the sections of lungs, a large number of the alveoli were filled with granular eosinophilic material. Cholesterol clefts were frequently seen in the material (Fig. 2). There were only a few macrophages in the material. Organization with fibroblasts and capillaries had developed in such intraalveolar material in some alveoli (Fig. 3). There were many focal thickening of the alveolar septae. Focally, the cells which lined the alveolar septae were hypertrophic and hyperplastic with vacuolated cytoplasm (Fig. 4). Nodules of caseous necrosis with little epithelioid reaction were also sporadically seen. The alveoli adjacent to these nodules were always filled with the intraalveolar material described above (Fig. 5). There were also many alveoli filled with the eosinophilic material that were not related to the caseous necrotic nodules. Ziehl-Neelsen staining demonstrated numerous acid-fast bacilli in these nodules of caseous necrosis. In such eosinophilic material in the alveoli adjacent to these nodules, there were also a few acid-fast bacilli. Apart from these nodules, acid-fast bacilli were hardly seen. Multifocal intraalveolar hemorrhages were also found.

The granular eosinophilic material in the alveoli was intensely positive with PAS staining and was resistant to diastase digestion. The PAS reaction was reversibly blocked by acetylation. The material showed weak metachromasia with

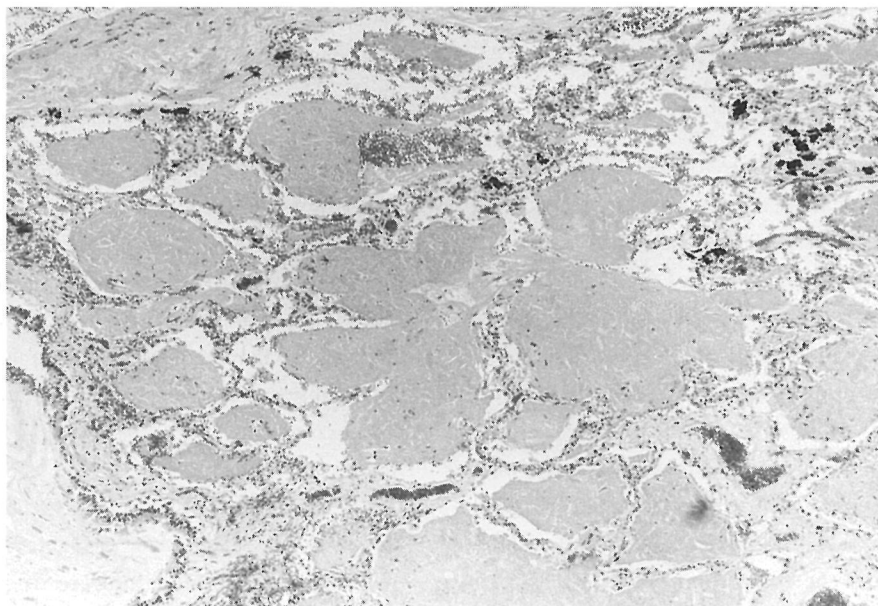


Fig. 2. Most alveoli are filled with eosinophilic material, in which cholesterol clefts are frequently seen. H.E.  $\times 140$ .

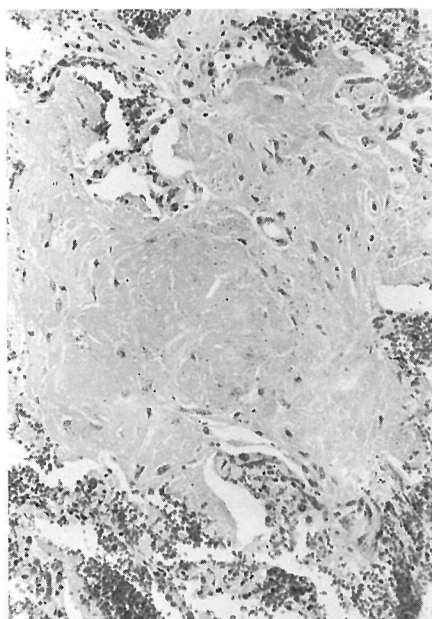


Fig. 3. Organization with fibroblasts and capillaries in the intra-alveolar material. H.E.  $\times 240$ .

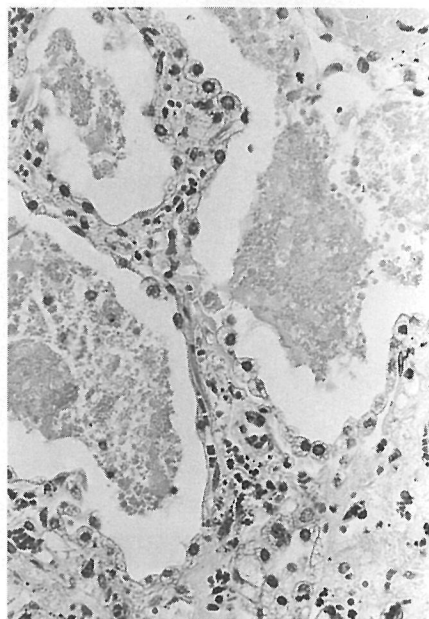


Fig. 4. Focal thickening of alveolar septa is seen. There are hypertrophic and hyperplastic lining epithelial pneumocytes with vacuolated cytoplasm. H.E.  $\times 470$ .



toluidine blue staining only when mounted under water, but it did not stain with alcian blue. No fibrin was detectable by PTAH staining. The material was also positive with Sudan III staining and Millon reaction.

PAS staining also demonstrated dense masses of fungi, which had both hyphae with septation and yeast forms. Most fungal masses were seen in the intraalveolar material. They tended to grow in a radial fashion. The walls of the fungi varied in width with occasional irregular contours (Fig. 6). Such a fungal growth was also observed in the spleen, liver, kidneys, urinary bladder and bone marrow. Grocott's methenamine silver staining also demonstrated the same fungal growth but not the growth of *Pneumocystis carinii*.

Numerous acid-fast bacilli were also demonstrated in the necrotic lymph nodes in the mediastinum and mesentery by Ziehl-Neelsen staining.

An electron-microscopic study showed that the alveolar spaces were filled with numerous

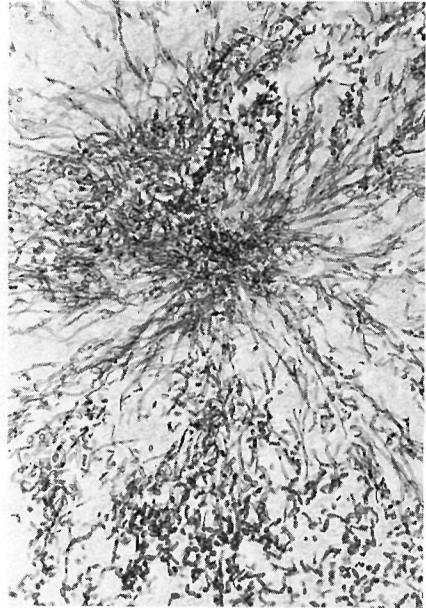


Fig. 6. Trichosporon grows radial fashion. Both hyphae with septation and yeast forms are seen. PAS.  $\times 470$ .

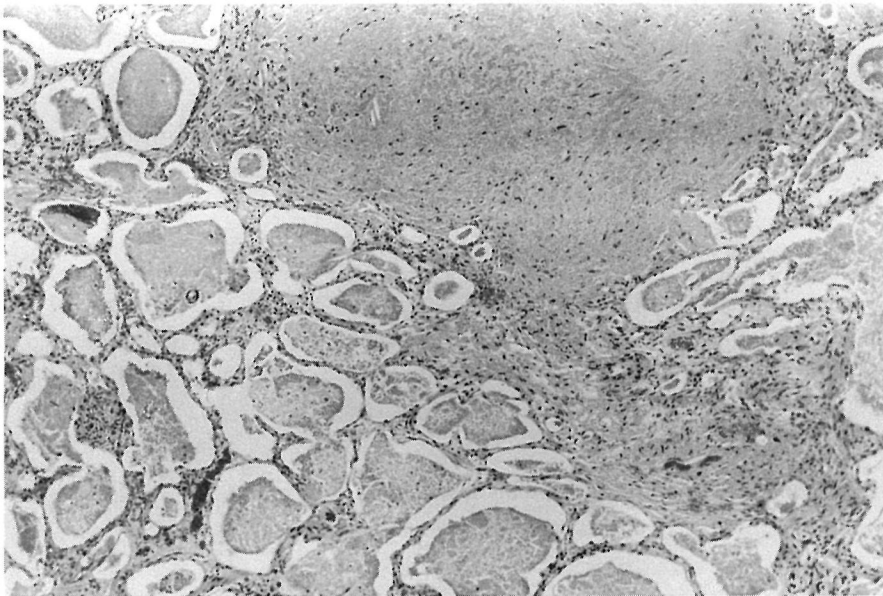


Fig. 5. A nodule of caseous necrosis with little epithelioid reaction. The adjacent alveoli are filled with eosinophilic granular material. H.E.  $\times 140$ .

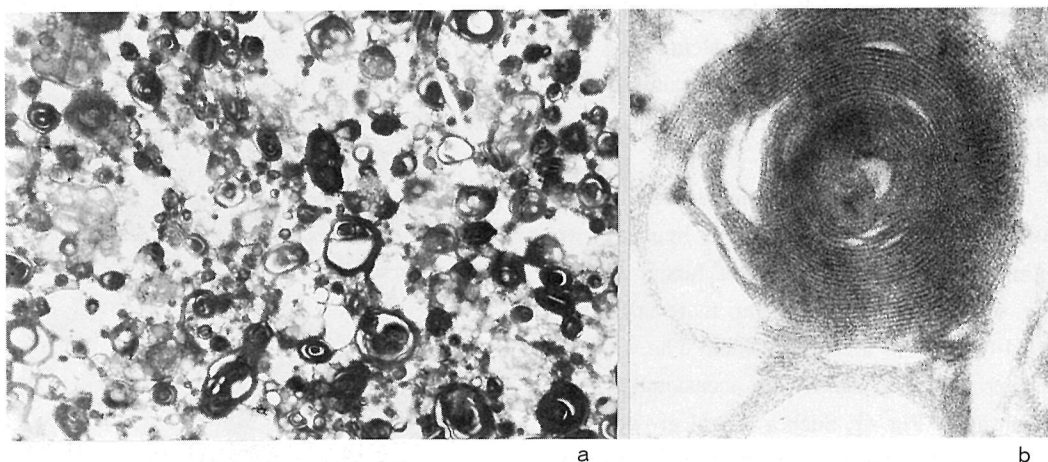


Fig. 7a. Numerous osmiophilic bodies in the alveolus. 7b. Distinct myelin-like figures are detected, 7a,  $\times 3500$ , 7b,  $\times 37500$ .

osmiophilic particulate with many myelin-like figures (Fig. 7). So called 'lamellar bodies' which are generally found in the type 2 pneumocytes were hardly seen. A few cells which lined the alveolar septae could not be characterized because of markedly vacuolated cytoplasm. We could not also characterize a few degenerative cells which were observed in the intraalveolar material.

In addition, the bone marrow showed a slight hypercellularity with an increase of myeloid cells and megakaryocytes. In the spleen, there were

marked congestion, fungal infection with necrosis and focal myeloid metaplasia, but the invasion of leukemic cells could not be found.

The pathological diagnosis was summarized in Table 1.

Table 1. Pathological diagnosis of the present case.

Chronic myelogenous leukemia, treated.

slight hypercellular bone marrow with an increase of myeloid cells and megakaryocytes.

1. Systemic *Trichosporon beigeli* infection.  
lungs, liver, kidneys, urinary bladder, spleen, bone marrow.
2. Disseminated tuberculosis.  
lungs, mediastinal & mesenteric lymph nodes.
3. Secondary pulmonary alveolar proteinosis, bilateral\*.
4. Pulmonary hemorrhages, bilateral.
5. Pleural effusion (80/100 ml).
6. Emaciation (171 cm/41 kg).

\* described in 'Discussion' in detail.

## Discussion

Pulmonary alveolar proteinosis, characterized by intraalveolar accumulation of large quantities of granular lipoproteinaceous material, was first described by Rosen et al. '58<sup>1)</sup>.

Thereafter, an increasing number of reports showed that similar lesions were sometimes observed in patients with a wide variety of hematological disorders. Among the approximately 44 cases of alveolar proteinosis associated with hematological disorders reported<sup>2-30)</sup>, 10 cases were associated with CML<sup>3,4,7,11,17,18,22,24,25,30)</sup> and 5 cases with tuberculosis<sup>4,7,19,22)</sup>.

In the present case, the intraalveolar material was intensely positive with PAS staining and resistant to diastase digestion. The PAS staining was reversibly blocked by acetylation. The material showed little metachromasia with toluidine blue staining and did not stain with alcian blue. No fibrin was detectable by PTAH. These findings suggest the presence of a nonglycogen carbohydrate in the material. Positive staining of the material for Sudan III and Millon reaction showed 'lipoproteinosis' in the literal sense of the words. These staining properties almost satisfy the classical characteristics of pulmonary alveolar proteinosis<sup>1)</sup>. Electron-microscopically, many myelin-like figures among numerous osmiophilic particulate components were found in the intraalveolar material. Such myelin-like figures were thought to be derived from degenerating cell membranes<sup>35)</sup>. These structures are distinctly different from the lamellar bodies which are found in the cytoplasm of type 2 pneumocytes and secreted from them<sup>36)</sup>. In the present case, the latter structures were hardly seen.

Biochemically, the major active components of alveolar surfactant are saturated phospholipids, predominantly dipalmityl lecithin (DPL). An autoradiographic study using <sup>3</sup>H-palmitate demonstrated that the lamellar bodies

correspond to DPL. Thus, the lamellar bodies are morphologically thought to be the major components of alveolar surfactant<sup>37)</sup>. Moreover, the activity of DPL as alveolar surfactant is stabilized by a certain apoprotein<sup>38)</sup>.

In 1983, Singh, et al. described that the intraalveolar material from patients with alveolar proteinosis without other associated diseases stained densely and uniformly for surfactant apoprotein by immunoperoxidase techniques, while that of patients with alveolar proteinosis associated with some hematological disorders stained only focally<sup>39)</sup>. Based on his data, it is possible to classify alveolar proteinosis into two groups, i.e., 1) idiopathic or primary alveolar proteinosis in which a large amount of surfactant apoprotein is demonstrated by immunohistochemical methods, and 2) secondary alveolar proteinosis in which a small amount of or no apoprotein is demonstrated although histochemical findings satisfy the classical criteria of alveolar proteinosis. Even by an electron-microscopical study, it would be possible to classify alveolar proteinosis into these two groups. In the intraalveolar material of the primary alveolar proteinosis, a large number of lamellar bodies are found, while that of the secondary alveolar proteinosis is mostly composed of myelin-like figures, that is, necrotic cell debris. Thus it is most likely that the present case is one of secondary alveolar proteinosis.

An electron-microscopic study for bronchoalveolar lavage effluents demonstrated that in the lavage from normal human lungs there are numerous lamellar bodies, i.e., major components of alveolar surfactant, and that in the lavage from lungs with idiopathic alveolar proteinosis there are many lamellar bodies surrounded by myelin-like structures<sup>36)</sup>.

In the present case, organization was seen in the material in some alveoli, and there were only few macrophages in the material. Thus, it is suggested that impairment of alveolar clearance by macrophages occurred. The nodules of caseous

necrosis containing acid-fast bacilli were also accompanied by little epithelioid reaction.

Pulmonary alveolar proteinosis was first described as a rare idiopathic disorder occurring in patients without other associated diseases<sup>1)</sup>. Several mechanisms have been proposed for it; e.g., the accumulation of cell debris<sup>1)</sup>, the overproduction of alveolar surfactant<sup>40)</sup> and the impairment of alveolar clearance<sup>4)</sup>. Overproduction of alveolar surfactant and/or impairment of alveolar clearance may be the cause of primary alveolar proteinosis, while secondary alveolar proteinosis may be due to the accumulation of cell debris and impairment of alveolar clearance.

As for secondary alveolar proteinosis, some authors believed that alveolar proteinosis with CML was closely associated with busulfan therapy<sup>13,18,30)</sup>. In the so-called 'busulfan lung', an electron-microscopic study has shown the presence in the alveolar space of desquamated and fragmented 'atypical' type 2 pneumocytes containing lamellar bodies<sup>41)</sup>. However, the majority of the patients of alveolar proteinosis with other hematological disorders had not received this drug. Secondary alveolar proteinosis has also been reported to occur in the lungs with a wide variety of opportunistic infections; e.g., aspergillosis, candidiasis, pneumocytosis and tuberculosis<sup>4)</sup>. The latter findings suggest the deterioration of the host defence mechanism, especially the cell-mediated immunity, as one of the causes of alveolar proteinosis. Green *et al.* speculated that the altered host cell-mediated immunity makes alveolar macrophages defective<sup>11)</sup>. Alveolar proteinosis with CML would not be triggered only by busulfan as proposed by some, as described above<sup>13,18,30)</sup>. It is likely that such a lesion is one of the pulmonary complications in immunosuppressive patients, especially those with hematological malignancies, through the defective activity of macrophages.

It has been speculated that alveolar proteinosis is closely associated with tuberculosis,

'69<sup>42)</sup>, '80<sup>43)</sup>. With respect to such an association, the following three hypotheses have been proposed: (1) Alveolar proteinosis is a secondary reaction to tuberculous infection, that stimulates type 2 pneumocytes to secrete abundant surfactant<sup>43)</sup>. (2) The intraalveolar material acts as a natural medium for the growth of mycobacterium, since it has been revealed *in vitro* studies that the growth of some fungi and mycobacterium tuberculosis can occur in the pulmonary washings of patients of alveolar proteinosis in the absence of other nutrients<sup>44)</sup>. (3) Focal areas of alveolar proteinosis-like lesion are caused by dissemination of caseous material with little or no cellular response of the alveoli<sup>42)</sup>.

The first hypothesis is not acceptable for the present case, since at least in the cases of alveolar proteinosis secondary to hematological disorders, there is only a little amount of surfactant in the intraalveolar material.

The present case may be mostly consistent with the second hypothesis. A small number of acid-fast bacilli, which had slowly proliferated in the intraalveolar material, might rapidly proliferate and disseminate in the terminal stage. Nevertheless, the third hypothesis can not be denied, although no mycobacterium was proven during the entire clinical course in spite of repeated sputum cultures.

In summary, we believe that the pathogenesis of the pulmonary lesions in the present case is as follows: Alveolar epithelial cells and/or inflammatory cells including inactivated alveolar macrophages which had desquamated were accumulated in the alveoli due to impairment of alveolar clearance, resulting alveolar proteinosis. And in such an accumulated material, the fungi and acid-fast bacilli might rapidly proliferate and disseminate in the terminal stage.

## Addendum

In the present case, *T. beigelii* was demonstrated by the blood culture, and the histological study of the autopsied specimens showed the hyphae and yeast forms characteristic of *T. beigelii*<sup>33,45</sup>. In addition, this fungus was identified by immunohistochemical techniques as *T. beigelii* on tissue sections by using rabbit antiserum to *T. beigelii* isolated from the patient 3 days before death<sup>46</sup>.

## References

1. Rosen, S.H., Castleman, B. & Liebow, A.A. (1958) Pulmonary alveolar proteinosis. N. Engl. J. Med. 258, 1123-1142.
2. Ajello, L. & Bignami, A. (1962) Proteinosis Alveolare Polmonare (Pneumoniosi Plasmorragica Didprotidemica Pneumoprotidose). Policlinico 69, 1433-1445.
3. Aymard, J.P., Gyger, M., Lavalley, R., Legresley, L.P. & Desy, M. (1984) A case of pulmonary alveolar proteinosis complicating chronic myelogenous leukemia: a peculiar pathologic aspect of busulfan lung? Cancer 53, 954-956.
4. Bedrossian, C.W.M., Luna, M.A., Conklin, R. H. & Miller, W.C. (1980) Alveolar proteinosis as a consequence of immunosuppression: a hypothesis based on clinical and pathologic observations. Hum. Pathol. 11, (suppl.) 527-535.
5. Bousser, J., Zittoun, R., Siguier, R., Godeau, P. & Bousser, M.G. (1973) Leucémie, Myélonocyttaire et Proteinose Alvéolaire Pulmonaire. Sem. Hôp. Paris 49, 507-511.
6. Breslow, A., Snow, P. & Rosenberg, M.H. (1965) Pulmonary alveolar proteinosis and chronic lymphatic leukemia. Med. Ann. D.C. 34, 209-212.
7. Carnovale, R., Zoranza, J., Goldman, A.M. & Luna, M. (1977) Pulmonary alveolar proteinosis: its association with hematologic malignancy and lymphoma. Radiology 122, 303-306.
8. Doyle, A.P., Balcerzak, S.P., Wells, C.L. & Crittenden, J.O. (1963) Pulmonary alveolar proteinosis with hematologic disorders. Ann. Int. Med. 112, 940-946.
9. Edmonson, W.R. & Gere, J.B. Pulmonary alveolar proteinosis. (1960) Ann. Int. Med. 52, 1310-1318.
10. Fraimow, W., Cathcart, R.T., Kirshner, J.J. & Taylor, R.C. (1960) Pulmonary alveolar proteinosis: a correlation of pathological and physiological findings in a patient followed up with serial biopsies of the lung. Am. J. Med. 28, 458-467.
11. Green, D., Dighe, P., Ali, N.O. & Katele, G.V. (1980) Pulmonary alveolar proteinosis complicating chronic myelogenous leukemia. Cancer 46, 1763-1766.
12. Jones, C.C. (1960) Pulmonary alveolar proteinosis with unusual complicating infections. Am. J. Med. 29, 713-722.
13. Kawai, T., Kouno, K., Aoki, N., Takenaka, M., Kondou, Y. & Itou, K. (1970) An autopsy case of pulmonary alveolar proteinosis associated with myelofibrosis. Rinshoketsueki 11, 562-563. (in Japanese).
14. Lakshminarayan, S., Schwarz, M.I. & Stanford, R.E. (1976) Unsuspected alveolar proteinosis complicating acute myelogenous leukemia. Chest 69, 433-435.
15. Levinson, B., Jones, R.S., Wintrobe, M.M. & Cartwright, G.E. (1958) Thrombocytopenia and pulmonary intra-alveolar coagulum in a young woman. Blood 13, 959-971.
16. Lorie, R., et al. (1973) Maladie de Waldenström avec Proteinose Alvéolaire Pulmonaire Terminale. Lyon Med. 226, 319-233.
17. Martinez-Maldonado, M. & Arellano, G.R. (1966) Pulmonary alveolar proteinosis,

- nocardiosis and chronic granulocytic leukemia. *South. Med. J.* 59, 901-905.
18. Miyashita, T., Ojima, A., Tuji, T., Tajima, T. & Watanabe, K. (1977) Varied pulmonary lesions with intraalveolar large lamellar bodies in an autopsy case with busulfan therapy. *Acta Pathol. Jpn.* 27, 239-249.
  19. Payneur, C.R., Knowaler, B.E. & Hyde, R. (1958) Pulmonary alveolar proteinosis. *Am. Rev. Tuberc.* 78, 906-915.
  20. Plenk, H.P., Swift, S.A., Chambers, W.L. & Peltzer, W.E. (1960) Pulmonary alveolar proteinosis: a new disease? *Radiology* 74, 928-938.
  21. Proks, C., Zamrazil, V. & Kuzma, J. (1966) Kahler's myeloma with cryoglobulinemia and pulmonary alveolar proteinosis. *Neplasia* 13, 218-222.
  22. Ruben, F.L. & Talamo, T.S. (1986) Secondary pulmonary alveolar proteinosis occurring in two patients with acquired immune deficiency syndrome. *Am. J. Med.* 80, 1187-1190.
  23. Schuler, D., Lapis, K., Matyas, B., Machay, T. & Akos, G. (1973) Unusual pulmonary complication of acute leukemia in children following complete hematologic remission. *Orv. Hetil.* 114, 2107-2111.
  24. Shober, R., Bensch, K.G., Kosek, J.C. & Northway, W.H. (1974) On the origin of the membranous intraalveolar material in pulmonary alveolar proteinosis. *Exp. Molec. Pathol.* 21, 246-258.
  25. Tourani, J.M., Troussard, X., Belghiti, D., Bernaudin, J.F. & Rochant, H. (1984) Protéinoase alvéolaire associée à une leucémie myéloïde chronique. *Presse. Med.* 13, 2019-2020.
  26. Williams, G.E.G., Medley, O.R.K. & Brown, R. (1960) Pulmonary alveolar proteinosis. *Lancet* 1, 1385-1388.
  27. Wuhrmann, V.F., Mark, G.J., Wick, A. & Mark, H.H. (1965) Alveolare Lungenproteinoase und Aspergillose mit Reaktiver Reticulose nach Silierungsarbeit. *Schweiz. Med. Wchschr.* 95, 1738-1744.
  28. Wuketich, S. (1963) Alveolarre Lungenproteinose. *Frankfurt. Z.Pathol.* 72, 571-575.
  29. Yamaguchi, K., Takahara, K. & Katsura, E.: An autopsy case of pulmonary alveolar proteinosis complicating acute lymphocytic leukemia. *Nipponbyorigakkaishi* 57, 154, 1968 (in Japanese).
  30. Yamamoto, M., Yamane, T., Hara, H., Takatomi, Y. & Kuramoto, A. (1975) Pulmonary alveolar proteinosis associated with chronic granulocytic leukemia. *Jap. J. Clin. Hematol.* 16, 347-353. (in Japanese)
  31. Rippon, J.W. (1974) *Medical Mycology*. 91-95. W.B.Saunders, Co., Philadelphia.
  32. Hoy, J., Hsu, K-C., Rolston, K., Hopfer, R.L., Luna, M. & Bodey, G.P. (1986) *Trichosporon beigelii* infection: A review. *Rev Infect. Dis.* 8, 959-967.
  33. Manabe, T., Moriya, T., Shirabe, T. & Takemoto, Y. (1986) Disseminated *Trichosporon beigelii* infection in a patient with malignant histiocytosis. *Acta Pathol Jpn.* 36, 1241-1250.
  34. Walsh, T.J., Newman, K.R., Moody, M., Wharton, R.C. & Wade, J.C. (1986) Trichosporosis in a patient with neoplastic disease. *Medicine* 65, 268-279.
  35. Trump, B.F. & Arstila, A.V. (1975) Cellular reaction to injury In "Principles of pathophysiology" ed. by Lavia, M.F. & Hill, R.B.Jr. p.9. Oxford University Press New York.
  36. Hook, G.E., Bell, D.Y., Gilmore, L.B., Nadeau, D., Reasor, M.J. & Talley, F.A. (1978) Composition of bronchoalveolar lavage effluents from patients with pulmonary alveolar proteinosis. *Lab. Invest.* 39, 342-359.
  37. Askin, F.B. & Kuhn, C. (1971) The cellular origin of pulmonary surfactant. *Lab. Invest.* 25, 260-268.
  38. King, R.J. & Macbeth, M.C. (1979) Physico-



- chemical properties of dipalmitoyl phosphatidylcholine after interaction with an apolipoprotein of pulmonary surfactant. Biochem. Biophys. Acta 557, 86-101.
39. Singh, G., Katyal, S.L., Bedrossian, C.W.M. & Rogers, R.M. (1983) Pulmonary alveolar proteinosis: staining for surfactant apoprotein in alveolar proteinosis and in conditions simulating it. Chest 83, 82-86.
  40. Larson, R.K. & Gordinier, R. (1965) Pulmonary alveolar proteinosis. Report of six cases, review of the literature and formulation of a new theory. Ann. Inn. Med. 62, 292-312.
  41. Litter, W.A., Kay, J.M., Hasleton, P.S. & Heath, D. (1969) Busulfan lung. Thorax 24, 639-655.
  42. Steer, A. (1969) Focal pulmonary alveolar proteinosis in pulmonary tuberculosis. Arch. Pathol. 87, 347-352.
  43. Reyes, J.M. & Putong, P.B. (1980) Association of pulmonary alveolar proteinosis with mycobacterial infection. Am. J. Clin. Pathol. 74, 478-485.
  44. Ramirez-Rivera, J., Savard, E.V. & Hawkins, J.E. (1966) Biological effect of pulmonary washings from cases of alveolar proteinosis. Am. Rev. Resp. Dis. 94, 244-246.
  45. Rivera, R. & Cangir, A. (1975) Trichosporon sepsis and leukemia. Cancer 36, 1106-1110.
  46. Mochizuki, T., Sugiura, H., Watanabe, S., Takada, M., Hodohara, K., Tatewaki, K. & Kushima, R. A case of disseminated *Trichosporon beigeli* infection diagnosed by the immunohistochemical method. Unpublished. (in Japanese)

## 続 発 性 肺 胞 蛋 白 症

### 一全身性トリコスపోーシス及び結核症を 合併した慢性骨髓性白血病の一部検例—

九嶋亮治<sup>1</sup>, 高田美雪<sup>2</sup>, 望月 隆<sup>3</sup>, 有菌直樹<sup>4</sup>, 惟任 修<sup>4</sup>, 岩井泰博<sup>4</sup>, 竹岡 成<sup>4</sup>

<sup>1</sup>滋賀医科大学附属病院検査部, <sup>2</sup>滋賀医科大学内科学第二講座, <sup>3</sup>皮膚科学講座, <sup>4</sup>病理学第一講座

肺胞蛋白症の所見を呈した慢性骨髓性白血病 (CML) の一部検例を報告する。結核症及び、まれな内臓真菌症である *Trichosporon beigeli* 感染症も同時に認められた。患者は69歳男性で、CML (Ph<sup>+</sup>) と診断されブスファン等にて治療されていたが、発熱を伴った強い呼吸不全で死亡した。剖検にて、多くの肺胞に eosinophilic で granular な物質が充満しているのが観察された。組織化学的には既に報告されている肺胞蛋白症の所見と同様であった。電顕的には、多くの myelin-like figures がオ

スミウム好性の球状物とともに見られた。さらに類上皮細胞反応の乏しい乾酪壊死による結節が散見され、無数の acid-fast bacilli が認められた。文献的に、血液疾患に伴った肺胞蛋白症は、今までに世界で44例報告されており、そのうち10例が CML と、5例が結核症と合併している。

我々は、血液疾患に続発した肺胞蛋白症は cell debris の蓄積と alveolar clearance の障害に基づくものであると考えている。