

## Antitumor effect of miriplatin-lipiodol suspension/emulsion using a VX2 liver tumor model

Yuki Tomozawa · Norihisa Nitta · Shinji Ohta · Hideji Otani ·  
Shobu Watanabe · Akinaga Sonoda · Keiko Tsuchiya ·  
Ayumi Nitta-Seko · Masashi Takahashi · Kiyoshi Murata

Received: 21 December 2012 / Accepted: 20 June 2013 / Published online: 5 July 2013  
© Japan Radiological Society 2013

### Abstract

**Objective** To evaluate the antitumor effects of miriplatin-lipiodol suspension and emulsion.

**Materials and methods** Fifty rabbits with VX2 liver tumors were randomly assigned to ten groups. Then, we prepared four types of mixtures: a suspension of lipiodol and miriplatin (ML), an emulsion of miriplatin dissolved with lipiodol and contrast medium (MLC) or saline (MLS), and saline alone (S). Ratios between lipiodol and contrast medium/saline volumes were 1:1/4, 1:1/2, 1:1, and 1:2 respectively. We used the same dose of miriplatin (2 mg/kg) and lipiodol (0.1 ml/kg) in each emulsion and suspension group. After intra-arterial infusion, the tumor growth rate was calculated, and sequential change of the plasma platinum concentration, the platinum concentration in the tumor and in surrounding normal liver tissue was also measured.

**Results** Among the ten groups, the tumor growth rate was lower in MLC and MLS groups, and the difference between tumor treated with MLS emulsion (ratio 1:1/2) and ML suspension was significant ( $p = 0.02$ ). The platinum concentration in the normal liver tissue was lower in MLS and MLC groups than in the ML group, and that in the tumor was higher in the MLS and MLC emulsion (ratio 1:1/2) groups.

**Conclusion** We suggest that miriplatin-lipiodol emulsion may be more effective than suspension.

**Keywords** Transcatheter arterial infusion · Miriplatin · Suspension · Emulsion

### Introduction

The incidence of hepatocellular carcinoma (HCC), one of the most common malignancies worldwide, is increasing [1]. Advances in its diagnosis and treatment have improved the prognosis of patients with HCC [2–5]; in those with inoperable HCC, transarterial chemoembolization (TACE) is the most important therapy. The efficacy and tumor selectivity of antitumor agents can be increased by injecting an embolic material or an oily lymphographic agent (LPD, Lipiodol Ultra-fluid; Guerbet, Aulnay-sous-Bois, France) via the hepatic artery. In Japan, several antitumor agents, e.g. cisplatin [6], doxorubicin [7], epirubicin [8], mitomycin C [9], and zinoastatin stimalamer [10], either suspended or emulsified in LPD have been studied clinically, and TACE, using emulsions of epirubicin with LPD or suspensions of cisplatin powder (DDPH, IA-call; Nippon Kayaku, Tokyo, Japan) in LPD followed by embolization with gelatin sponges, is now widely used to treat patients with HCC [11].

Miriplatin (Miripla; Dainippon Sumitomo Pharma, Osaka, Japan), a novel lipophilic platinum complex with a high affinity for LPD, has been developed to treat HCC [12]. Because of its chemical properties, miriplatin is expected to yield a more stable chemoembolic compound than the previously-used emulsions of water-soluble anti-tumor agents and LPD. In animals and humans, the intra-hepatic arterial administration of miriplatin suspended in LPD manifested antitumor effects against hepatic tumors [13–17], and Okusaka et al. [16] and Fujiyama et al. [18] suggested the use of 20 mg/ml miriplatin suspended in LPD to treat patients with HCC.

Y. Tomozawa (✉) · N. Nitta · S. Ohta · H. Otani ·  
S. Watanabe · A. Sonoda · K. Tsuchiya · A. Nitta-Seko ·  
M. Takahashi · K. Murata  
Department of Radiology, Shiga University of Medical Science,  
Seta Tsukinowa-cho, Otsu City, Shiga 520-2192, Japan  
e-mail: tomozawa@belle.shiga-med.ac.jp

Research has demonstrated that the administration of an epirubicin suspension is a superior form of TACE compared to that of administration of an epirubicin emulsion, with the suspension form being found superior to the emulsion form in maintaining sustained agent release [19]. Although miriplatin has a different chemical property compared with the water-soluble antitumor agents, no study to date has compared the antitumor efficacy of miriplatin-LPD suspensions and emulsions.

In this article, using a rabbit transplanted VX2 liver cancer model we evaluated the antitumor effect of suspensions (without solution) and emulsions (with solution) of miriplatin-LPD and estimated the relevant mixture ratios of miriplatin, contrast medium or saline, and LPD.

## Materials and methods

### VX2 liver tumor model and experimental groups

Our study was approved by the ethics committee of our institution and abided by the regulations covering the care and use of experimental animals. We induced the liver tumors using the method of Haaga et al. [20]. Briefly, one Japanese white rabbit hosting a transplanted VX2 liver tumor was purchased from Japan SLC, Inc. (Tokyo, Japan). When the tumor diameter reached 30 mm, the tumor was harvested. Under sterile conditions,  $2 \times 2 \times 2$ -mm pieces of tumor tissue were dissected, placed in 10 % dimethyl sulfoxide with 80 % Hanks' balanced salt solution, and 10 % bovine serum in pure calf serum, and stored in liquid nitrogen until use at which time they were thawed rapidly at 36 °C. We anesthetized 50 adult Japanese white rabbits weighing 2.5–3.5 kg (Japan SLC, Inc.) with an intramuscular (i.m.) injection of medetomidine hydrochloride (0.1 mg/kg, Meiji Seika Co. Ltd., Tokyo, Japan) and ketamine hydrochloride (25 mg/kg, Sankyo Yell Yakuhin Co. Ltd., Tokyo, Japan). For tumor implantation, a small midline incision was made at the subxiphoid process, the left medial lobe of the liver was exposed and exteriorized, and a  $2 \times 2 \times 2$ -mm piece of VX2 tumor was implanted. The abdominal muscles and skin were then closed with an absorbable suture. The transplanted rabbits were injected with 1.0 ml of 2.5 % enrofloxacin (2.5 mg/kg, i.m.; Bayer

Healthcare Co. Ltd., Tokyo, Japan) once a day for 3 consecutive days and used for our experiments 2 weeks after implantation when the tumors were 15–30 mm in diameter.

Then, we randomly divided the 50 rabbits with transplanted VX2 liver tumors into ten groups. We prepared four types of mixtures: a suspension of miriplatin (2 mg/kg) and LPD (0.1 ml/kg) (ML group), an emulsion of miriplatin dissolved with LPD and contrast medium (MLC group) or saline (MLS group), and 0.1 ml/kg saline alone [S (control) group]. In case of the MLC group or MLS group, the ratio of LPD to the volume of contrast medium or saline was 1:1/4, 1:1/2, 1:1, and 1:2. Consequently, a total of 10 solutions were studied (Table 1). The dose of the administered agents was based on the maximum dose used in adult humans with a mean body weight of 60 kg. Each combination of contrast medium or saline and LPD was introduced into a disposable syringe, and two syringes were connected to a three-way stopcock. The syringes were swung by a pumping method, which made 20 trips.

### Transarterial infusion

Two weeks after VX2 implantation we performed transarterial infusion under X-ray fluoroscopic guidance. The rabbits were placed under general anesthesia with the above-mentioned method, an incision was made to expose the right femoral artery, and a 4-Fr sheath (S1 sheath; Terumo Clinical Supply, Gifu, Japan) was introduced. Then a 4-Fr cobra-type catheter (Selecon catheter; Terumo Clinical Supply) was inserted in the trunk of the celiac artery and celiac arteriographs were obtained by manually injecting 2 ml of 50 % diluted iopamidol (Bayer Health Care Co. Ltd., Osaka, Japan.). A 2.1-Fr microcatheter (Sniper 2 selective type; Terumo Clinical Supply Co. Ltd.) was then inserted into the left hepatic artery and the suspension and emulsion which had been prepared at room temperature were delivered via a catheter inserted in the left hepatic artery, taking care to avoid reflux. Then the catheter and sheath were removed, and the femoral artery was ligated.

### Evaluation of antitumor effects

Using 0.3 T MR scans (AIRIS II Comfort, Hitachi Medical Corp., Tokyo, Japan) we calculated the growth rate of the

**Table 1** 10 Types of miriplatin-lipiodol suspension and emulsions

	ML	MLS 1/4	MLS 1/2	MLS 1	MLS 2	MLC 1/4	MLC 1/2	MLC 1	MLC 2	S
M	2	2	2	2	2	2	2	2	2	0
L	0.1	0.1	0.1	0.1	0.1	0.1	0.1	0.1	0.1	0
S or C	0	0.025	0.05	0.1	0.2	0.025	0.05	0.1	0.2	0.1

M miriplatin (mg/kg), L lipiodol (ml/kg), S saline (ml/kg), C contrast medium (ml/kg)

implanted VX2 tumors before and 1 week after the delivery of the intra-arterial infusions. The scan parameters were: field of view 150 mm, T1-weighted images (TR 300 ms, TE 14.0 ms, flip angle 90°, slice thickness and interval 3.0 mm, matrix size 256 × 256). The liver tumor volumes were estimated using Photoshop 7.0.1 (Adobe Systems Inc., CA, USA). Briefly, two radiologists manually outlined the tumors on multiple contiguous MRI slices by consensus. Then the tumor dimensions on each slice were added with the assigned values representing the total number of pixels within the outline. The VX2 tumors easily created necrosis by themselves, therefore the visible necrotic lesion observed as an obviously abnormal intensity area was removed in the measurement of tumor volume. The growth rate (%) was calculated by comparing the tumor volume recorded before ( $V_b$ ) and 1 week after ( $V_a$ ) treatment using the formula:  $(V_a/V_b) \times 100$ .

Furthermore, we recorded the sequential changes observed within the first 24 h in plasma platinum concentration; the platinum concentration surrounding normal liver tissue and in the tumors were also measured. Plasma platinum concentrations were assayed immediately after, and at 10, 30, and 60 min, 24 h, and 7 days after the inoculations; 1 week after intra-arterial delivery of mi-riplatin-LPD suspension or emulsion, the rabbits were sacrificed at the indicated times and the platinum concentration in the tumors and in the normal tissue surrounding the tumors was recorded. The platinum concentrations were measured at Nac Co., Ltd., Tokyo, Japan. The atomic absorption spectrometer used was a SIMAA 6000 (Perkin Elmer, Inc. MA, USA), its detection limit for platinum was 0.05 µg/ml for blood and 0.01 µg/g for tissue.

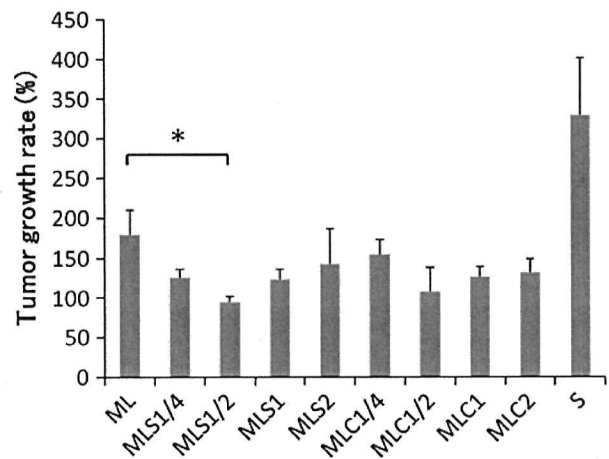
#### Statistical analysis

Statistical analysis was performed with Dr. SPSS II for Windows (SPSS Japan Inc., Tokyo, Japan). To assess significant differences in the tumor growth rates we used Tukey's HSD test. Differences in the platinum concentration in the VX2 tumors and in the normal livers were determined with a one-tailed Student's *t*-test. Differences of  $p < 0.05$  were considered statistically significant.

#### Results

Transarterial infusion was successful in all rabbits, none died within 1 week after the procedure.

The tumor growth rate in the VX2-bearing rabbits inoculated with the ML suspension and saline was  $179 \pm 32$  and  $329 \pm 71$  %. It was  $126 \pm 11$ ,  $94 \pm 8$ ,  $124 \pm 13$ , and  $142 \pm 44$  % in rabbits inoculated with the

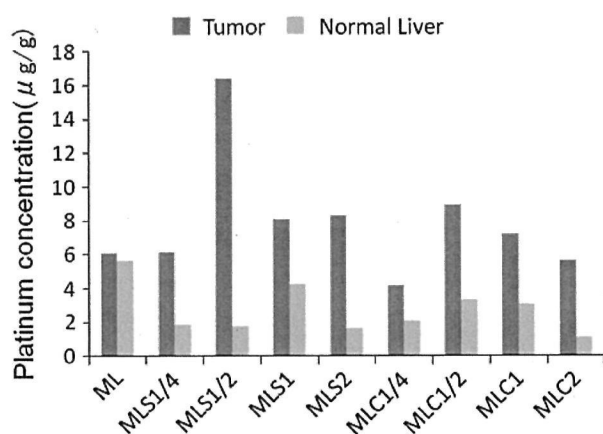


**Fig. 1** Tumor growth rate. The tumor growth rate tended to be lower in MLC and MLS groups. There was a significant difference between the ML group and the MLS 1/2 group ( $p = 0.02$ )

MLS emulsion at ML:saline ratios of 1:1/4, 1:1/2, 1:1 and 2:1 respectively, and  $155 \pm 18$ ,  $107 \pm 32$ ,  $127 \pm 12$ , and  $132 \pm 18$  % in rabbits inoculated with the MLC emulsion at these ratios, respectively (Fig. 1). The tumor growth rate was significantly lower in rabbits treated with the emulsions than in the saline-inoculated controls ( $p < 0.05$ ). Although the tumor growth rates in the MLC and MLS groups were lower than that in the ML group, most comparisons of the growth rate between suspension and emulsion groups were not statistically significant. However, the difference between tumors treated with the ML suspension and the MLS emulsion (ratio 1:1/2) was significant ( $p = 0.02$ ).

In all ten groups the total plasma platinum concentration remained below the level of detection at all examined post-inoculation time points.

The platinum concentration in the tumor and in the normal liver tissues was  $6.09 \pm 6.41$  and  $5.66 \pm 7.56$ , respectively in the ML group, the corresponding values were  $6.14 \pm 6.52$  and  $1.88 \pm 2.67$  in the MLS 1/4 group,  $16.43 \pm 19.17$  and  $1.77 \pm 2.64$  in the MLS 1/2 group,  $8.10 \pm 7.98$  and  $4.23 \pm 5.92$  in the MLS 1 group,  $8.30 \pm 6.91$  and  $1.65 \pm 1.76$  in the MLS 2 group,  $4.20 \pm 3.95$  and  $2.11 \pm 2.11$  in the MLC 1/4 group,  $8.96 \pm 8.85$  and  $3.34 \pm 3.94$  in the MLC 1/2 group,  $7.25 \pm 5.30$  and  $3.12 \pm 3.98$  in the MLC 1 group, and  $5.64 \pm 5.77$  and  $1.15 \pm 1.47$  in the MLC 2 group (Fig. 2). Although there were no significant differences between the suspension group and the emulsion groups, the platinum concentration in the normal liver tissue was lower in MLS and MLC groups than in the ML group, and the platinum concentration in the tumor was higher in the MLS 1/2 and MLC 1/2 groups.



**Fig. 2** Platinum concentration in tumor and in normal liver tissue. The platinum concentration in normal liver tissue tended to be lower in the MLS and MLC groups than in the ML group, and the platinum concentration in the tumor tended to be higher in the MLS 1/2 group and MLC 1/2 group

## Discussion

Since 2005, DDPH, a fine-powder formulation of CDDP, has been available in Japan for intra-arterial delivery in HCC patients [21]. Consequently, TACE with a DDPH-LPD suspension is now widely performed in Japan, and its efficacy for treating HCC has been reported [11, 21]. However, as DDPH is hydrophilic, its suspension in LPD is unstable and only a small amount of cisplatin remains in the tumor over a prolonged period. Most of the agent is released rapidly from the suspension into systemic circulation, causing systemic side effects.

Miriaplatin, a third-generation platinum preparation with a diaminocyclohexane structure was designed for the transarterial treatment of HCC. It is a platinum complex containing myristate, a 14-carbon fatty acid. Due to its lipophilic properties, it can be suspended easily in LPD by being shaken gently by hand, and when a suspension of miriaplatin with LPD is administered intra-arterially, LPD acts as a carrier of miriaplatin. ML suspensions selectively accumulate and persist in the tumor, gradually releasing active platinum compounds into tumor tissues over a long time period. Due to this novel attribute, ML suspensions may exert long-acting antitumor effects, rendering them superior to other hydrophilic chemotherapeutic agents. In addition, rapid release into the systemic circulation is inhibited, resulting in minimal whole-body exposure and a reduction in adverse systemic side effects such as nausea/vomiting, renal damage, and other acute toxic events [13, 16]. However, the optimal way of suspending miriaplatin in LPD remains still unknown.

Sustained release cannot be expected by merely dissolving LPD with anti-cancer drugs, and it has been

reported that sustained release and antitumor effects can be expected in emulsions of water-in-oil (water droplets dispersed in oil) or in suspension form [22]. Moreover, previous research provided evidence that the ratio of tumor to nontumorous liver uptake of iodized oil was significantly higher with water-in-oil emulsions than with pure iodized oil or oil-in-water (oil droplets dispersed in water) emulsions after intra-arterial hepatic injection in rabbits bearing VX2 tumors in the liver [23].

In this study, the tumor growth rate in the miriaplatin-LPD emulsion groups was found to be lower than that in the suspension group, and the platinum concentration in the normal liver tissue was found to be lower in ML emulsion than ML suspension-treated rabbits. This could be because a droplet of emulsion is larger than a droplet of suspension due to its high viscosity [23], which limits its entrance into the thin vessels supplying the liver parenchyma, and increases tumor uptake of miriaplatin and LPD. Another reason we considered was that contrast medium or saline acts as a surfactant for the miriaplatin-LPD suspension form and facilitates the release of platinum from it by increasing its surface area.

In the therapeutic groups, tumors treated with emulsions in which the LPD: saline and LPD:contrast medium ratios were 1:1/2 exhibited a lower growth rate and the tumor platinum concentration in those two emulsion groups was higher than that in the other groups. This result could be explained by the difference between water-in-oil emulsion and oil-in-water emulsion. Among the types of mixtures, water-in-oil emulsions have been found to exert a stronger embolic effect in HCC treatment compared to oil-in-water emulsions, as well as a greater capacity for sustained release [24]. In our study, the solutions of MLS 1/4, MLS 1/2, MLC 1/4 and MLC 1/2 were equivalent to water-in-oil emulsions. However, only 0.075 ml saline or contrast medium was added in ML suspension in MLS 1/4 and MLC 1/4 solutions, and we assumed that the absolute volume of saline and contrast medium was too small to form a water-in-oil emulsion. Another reason was that adding a greater volume of contrast medium or saline to the ML suspension caused the concentration of miriaplatin to decrease, while the efficacy of ML suspension depended on the miriaplatin concentration. Based on their miriaplatin concentration escalation study, Fujiyama et al. [18] recommended a dose of 20 mg/ml, and the concentration of miriaplatin in the MLS 2 and MLC 2 groups was one-third of the recommended dose. Therefore, the adequate dose of the contrast medium or saline which was added to LPD was considered to be the half volume of LPD.

In our study, the detection limit for total plasma platinum concentration in blood was 0.05 μg/ml, and its concentration in rabbit blood remained below the detection level at all time-points. We attribute this to the highly



lipophilic nature of miriplatin; only a limited amount of platinum is released from ML suspensions as free platinum, which may account for the undetectable platinum concentration in rabbit plasma. Moreover, the small amount of released miriplatin was present in blood as the active form of miriplatin hydrate (DPC) that characteristically binds to protein in plasma and disappears rapidly [25].

Our study has some limitations. Because of the limited number of rabbits we could not show significant differences in the majority of the results, and could show only the tendency. Another limitation is that we did not evaluate liver function in the current experiment, therefore we could not actually prove the finding that ML emulsion had less influence on the normal liver tissue than the suspension form.

Although at present miriplatin is available for clinical use only in Japan, we expect that its efficacy will be confirmed and that it will soon become available elsewhere to treat the increasing number of patients with liver cancer. Recently, TACE with drug-eluting beads for HCC treatment has become widely used in western countries [26, 27], although use of these particles is not permitted in Japan. Furthermore, the molecular-targeted agent sorafenib has been found to significantly prolong survival in patients with HCC [28] and the guidelines on the use of miriplatin and sorafenib for the treatment of HCC have been prepared [29]. In the near future, a wider choice of treatment for patients with unresectable HCC would improve their prognosis.

In this study we did not use embolizing agents such as gelatin sponge, although Imai et al. [30] reported that the addition of embolizing agents to a treatment regimen using ML suspension could be safely used for HCC. We need to assess the efficacy and safety of arterial chemoembolization using ML emulsion and embolizing agents compared to arterial infusion alone.

In conclusion, this study found that ML emulsions (water-in-oil) have superior anticancer efficacy compared to ML suspensions in the treatment of hepatic tumors. Further clinical trials are necessary to compare the antitumor effects of TACE with ML emulsion to that of TACE with ML suspension.

**Conflict of interest** We declare that we have no conflict of interest.

## References

- Kamangar F, Dores GM, Anderson WF. Patterns of cancer incidence, mortality, and prevalence across five continents: defining priorities to reduce cancer disparities in different geographic regions of the world. *J Clin Oncol*. 2006;24:2137–50.
- Vogl TJ, Naguib NN, Nour-Eldin NE, Rao P, Emami AH, Zangos S, et al. Review on transarterial chemoembolization in hepatocellular carcinoma: palliative, combined, neoadjuvant, bridging, and symptomatic indications. *Eur J Radiol*. 2009;72:505–16.
- Llovet JM, Bruix J. Systematic review of randomized trials for unresectable hepatocellular carcinoma: chemoembolization improves survival. *Hepatology*. 2003;37(2):429–42.
- Lau WY, Lai EC. Hepatocellular carcinoma: current management and recent advances. *Hepatobiliary Pancreat Dis Int*. 2008;7(3):237–57.
- Achenbach T, Seifert JK, Pitton MB, Schunk K, Junginger T. Chemoembolization for primary liver cancer. *Eur J Surg Oncol*. 2002;28(1):37–41.
- Yamamoto K, Shimizu T, Narabayashi I. Intra-arterial infusion chemotherapy with lipiodol-CDDP suspension for hepatocellular carcinoma. *Cardiovasc Interv Radiol*. 2000;23:26–39.
- Shimamura Y, Gunven P, Takenaka Y, Shimizu H, Shima Y, Akimoto H, et al. Combined peripheral and central chemoembolization of liver tumors. Experience with lipiodol-doxorubicin and gelatin sponge (L-TAE). *Cancer*. 1988;61:238–42.
- Kobayashi S, Narimatsu Y, Ogawa K, Hashimoto S, Nakatsuka S, Miura H, et al. Transcatheter hepatic arterial chemoembolization using epirubicin-lipiodol: experimental and pharmacological evaluation. *Cancer Chemother. Pharmacol*. 1992; 31(Suppl.): S45–50.
- Ohnishi K, Sugita S, Nomura F, Iida S, Tanabe Y. Arterial chemoembolization with mitomycin C microcapsules followed by transcatheter hepatic artery embolization for hepatocellular carcinoma. *Am J Gastroenterol*. 1987;82:876–9.
- Okusaka T, Okuda S, Ueno H, Ikeda M, Iwata R, Furukawa H, et al. Transcatheter arterial embolization with zinstatin stimulant for hepatocellular carcinoma. *Oncology*. 2002;62:228–33.
- Kasai K, Ushio A, Sawara K, Miyamoto Y, Kasai Y, Oikawa K, et al. Transcatheter arterial chemoembolization with a fine powder formulation of cisplatin for hepatocellular carcinoma. *World J Gastroenterol*. 2010;16(27):3437–44.
- Maeda H, Uchida NA, Sasaki T. Liposoluble platinum (II) complexes with antitumor activity. *Jpn J Cancer Res*. 1986;77:523–5.
- Kishimoto S, Noguchi T, Yamaoka T, Fukushima S, Takeuchi Y. Antitumor effects of a novel lipophilic platinum complex (SM-11355) against a slowly-growing rat hepatic tumor after intra-hepatic arterial administration. *Biol Pharm Bull*. 2000;23:344–8.
- Hanada M, Baba A, Tsutsumishita Y, Noguchi T, Yamaoka T, Chiba N, et al. Intra-hepatic arterial administration with miriplatin suspended in an oily lymphographic agent inhibits the growth of tumors implanted in rat livers by inducing platinum-DNA adducts to form and massive apoptosis. *Cancer Chemother Pharmacol*. 2009;64:473–83.
- Hanada M, Baba A, Tsutsumishita Y, Noguchi T, Yamaoka T. Intra-hepatic arterial administration with miriplatin suspended in an oily lymphographic agent inhibits the growth of human hepatoma cells orthotopically implanted in nude rats. *Cancer Sci*. 2009;100:189–94.
- Okusaka T, Okada S, Nakanishi T, Fujiyama S, Kubo Y. Phase II trial of intra-arterial chemotherapy using a novel lipophilic platinum derivative (SM-11355) in patients with hepatocellular carcinoma. *Invest New Drugs*. 2004;22:169–76.
- Ikeda K, Okusaka T, Ikeda M, Morimoto M. Transcatheter arterial chemoembolization with a lipophilic platinum complex SM-11355 (miriplatin hydrate). Safety and efficacy in combination with embolizing agents. *Gan to kagaku ryoho*. 2010;37(2):271–5.
- Fujiyama S, Shibata J, Maeda S, Tanaka M, Noumaru S, Sato K, et al. Phase I clinical study of a novel lipophilic platinum complex (SM-11355) in patients with hepatocellular carcinoma refractory to cisplatin/lipiodol. *Br J Cancer*. 2003;89:1614–9.
- Ueda T, Murata S, Mine T, Onozawa S, Onda M, Naito Z, et al. Comparison of epirubicin-iodized oil suspension and emulsion

- for transcatheter arterial chemoembolization in VX2 tumor. *Sci World J*. Epub 2012; p 7. doi:10.1100/2012/961986 (Article ID 961986).
20. Haaga JR, Exner AA, Wang Y, Stowe NT, Tarcha PJ. Combined tumor therapy by using radiofrequency ablation and 5-FU-laden polymer implants: evaluation in rats and rabbits. *Radiology*. 2005;237(3):911–8.
  21. Yamashita Y, Taketomi A, Itoh S, Harimoto N, Morita K, Fukuhara T, et al. Phase I/II study of the lipiodolization using DDP-H (CDDP powder; IA-call) in patients with unresectable hepatocellular carcinoma. *Cancer Chemother Pharmacol*. 2010;65:301–7.
  22. Yamashita Y, Nakagawa N, Miyawaki M. Experimental study of hepatic arterial embolization therapy by various formulations of anti-cancer agent lipiodol. *Nippon Acta Radiol*. 1985;45(10):1313–21.
  23. de Baere T, Zhang X, Aubert B, Harry G, Lagrange C, Ropers J, et al. Quantification of tumor uptake of iodized oils and emulsions of iodized oils: experimental study. *Radiology*. 1996;201:731–5.
  24. Demachi H, Matsui O, Abo H, Tatsu H. Simulation model based on non-Newtonian fluid mechanics applied to the evaluation of the embolic effect of emulsions of iodized oil and anticancer drug. *Cardiovasc Intervent Radiol*. 2000;23:285–90.
  25. Luo FR, Yen TY, Wyrck SD, Chaney SG. High performance liquid chromatographic separation of the biotransformation products of oxaliplatin. *J Chromatogr B*. 1999;724:345–56.
  26. Malagari K, Chatzimichael K, Alexopoulou E, Kelekis A, Hall B, Dourakis S, et al. Transarterial chemoembolization of unresectable hepatocellular carcinoma with drug eluting beads: results of an open-label study of 62 patients. *Cardiovasc Intervent Radiol*. 2008;31:269–80.
  27. Lammer J, Malagari K, Vogl T, Pilleul F, Denys A, Watkinson A, et al. Prospective randomized study of doxorubicin-eluting-bead embolization in the treatment of hepatocellular carcinoma: results of the PRECISION V study. *Cardiovasc Intervent Radiol*. 2010;33:41–52.
  28. Llovet JM, Ricci S, Mazzaferro V, Hilgard P, Gane E, Blanc JF, et al. Sorafenib in advanced hepatocellular carcinoma. *N Engl J Med*. 2008;359(4):378–90.
  29. Kaneko S, Furuse J, Kudo M, Ikeda K, Honda M, Nakamoto Y, et al. Guideline on the use of new anticancer drugs for the treatment of hepatocellular carcinoma 2010 update. *Hepatol Res*. 2012;42(6):523–42.
  30. Imai N, Ikeda K, Kawamura Y, Sezaki H, Hosaka T, Akuta N, et al. Transcatheter arterial chemotherapy using miriplatin-lipiodol suspension with or without embolization for unresectable hepatocellular carcinoma. *Jpn J Clin Oncol*. 2012;42:175–82.