

A Case of Malignant Fibrous Histiocytoma

—The Use of Tissue Culture for Identification of the Histiocytic Nature of the Tumor Cells—

Hidetoshi OKABE¹, Minoru IMOKAWA¹, Yukio OCHI¹, Masaki KOKUHO²,
Eisuke HAYASHIDA², Tadao TOMOYOSHI² and Osamu TAKEOKA³

¹Department of Laboratory Medicine, ²Department of Urology & ³First Department of Pathology, Shiga University of Medical Science

A case of pleomorphic malignant fibrous histiocytoma was successfully diagnosed by using tissue culture analysis. Many of the cultivated tumor cells displayed rapid movements as well as phagocytic activities, and the attitude appeared characteristic for histiocytic cells. On the other hand, the remaining minor population revealed relatively poor movements. The intermediate filaments seen in the cultured tumor cells were composed of vimentin which was distributed unevenly in the actively moving cells. In the cells with poor movements, the distribution of vimentin was relatively even. Thus, the distribution of this filament seems to have some correlation with the cellular motility.

Key word : malignant fibrous histiocytoma, tissue culture, vimentin

Introduction

Malignant fibrous histiocytoma is the most common type malignant neoplasm of soft tissue. Histologically, several subtypes including a pleomorphic type have been classified (1). The pleomorphic type such as this case is sometimes difficult to distinguish from other kinds of pleomorphic tumors such as rhabdomyosarcomas or from anaplastic carcinomas (1). However, as shown by Ozzello and Iwasaki, cultured cells of the malignant fibrous histiocytoma are

known to have histiocytic movements including pseudopodia formation and phagocytosis (2-4). Therefore, detection of such movements in tissue culture condition should be valuable for precise diagnosis. Here, we report a case of pleomorphic malignant fibrous histiocytoma in which tissue culture analysis was useful for the diagnosis.

Case

Sixty three years old male was admitted to the Hospital of Shiga University of Medical Sci-

Accepted for publication December 1, 1986

岡部英俊, 芋川 実, 越智幸男, 国保昌紀, 林田英資, 友吉唯夫, 竹岡 成

Mailing address : Shiga University of Medical Science, Otsu, Shiga, 520-21, JAPAN

ence on January 6th of 1986 because of an abdominal tumor which was noticed by himself in July of 1985. The tumor had been growing rapidly, and he began to feel general malaise since October of that year and lost 8kgr of body weight during the next three months. There was no spontaneous pain on the tumor.

Before the admission to the university hospital, prominent urinary sugar excretion was detected. A mild degree of hypertension with systolic pressure ranging 160–180 mmHg had continued during the past 26 years and was controlled with oral antihypertensive drugs. Neither special familial nor past history related to this tumor was detected.

Angiographic study revealed a huge tumor in the left side of the retroperitoneum which was fed by branches of the lumbar arteries I-III and the inferior mesenteric artery. Left kidney controur could not be visualized by IVP. Retrograde pyelography revealed obstruction of the ureter at 21cm oral from the urethral orifice, probably due to compression from the outside and hydronephrotic change in the proximal portion of this obstruction.

On 29th January, 1896, laparotomy was done but total resection of the tumor was impossible since it was too large and spreaded widely. Then,

a part of the tumor was excised and submitted for pathological study and tissue cultural analysis.

Although chemotherapy was given postoperatively, the tumor growth did not subside and patient was expired on May 15, 1986 due to cachexia and systemic spread of the tumor, particularly in the lungs.

Preparation of Histopathological and Tissue Culture Studies : For the histopathological study, a half of the tumor was fixed with neutral formalin, embedded in paraffin and processed for light microscopic study using H&E, PAS and PTAH stainings. In addition, immunohistochemical stainings for myoglobin, keratin and lysozyme were done by using polyclonal antibodies (DAKO) and MBL's universal PAP kit.

The remaining half of the tumor tissue was minced under a sterile condition and explanted in plastic culture flasks (Falkon 3013). The cultivation was carried out in a CO₂ incubator (36 °C, 5% CO₂). The medium was composed of 90% RPMI 1640 (Flow) supplemented with 10% fetal bovine serum (GIBCO) and 4.6mg/l of insulin (Sigma). Some of the minced fragments were plated on coverslips and processed for the immunohistochemical study after fixation with cold acetone. The antibodies used for this study were the same

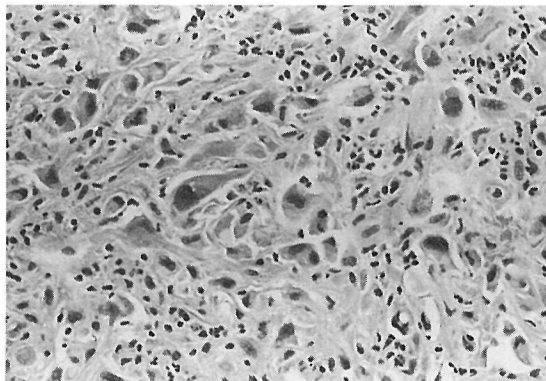


Fig. 1. Large pleomorphic cells are randomly dispersed. No special arrangements can be seen. (H & E x 100)

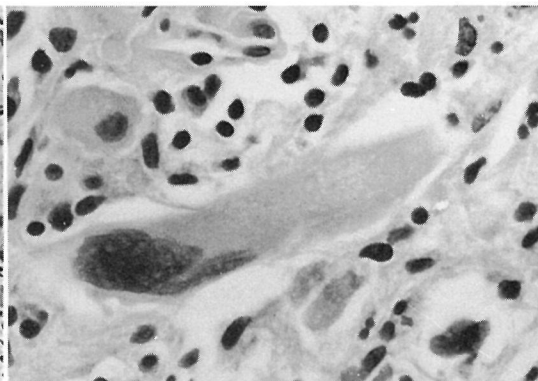


Fig. 2. A multinucleated giant cell with elongated eosinophilic cytoplasm. (H & E x 200)

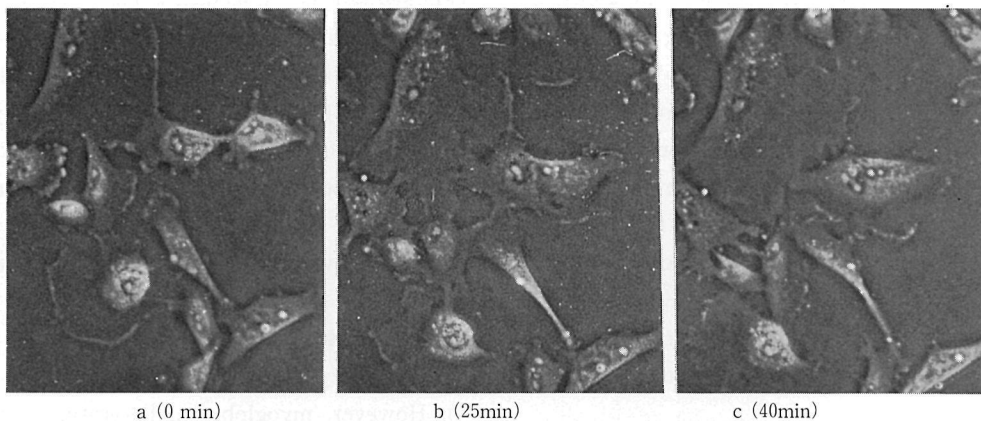


Fig. 3. abc. Active movements with pseudopodia formation and multinucleation by cell fusion in the tissue culture (Time-lapse phase contrast x 25)

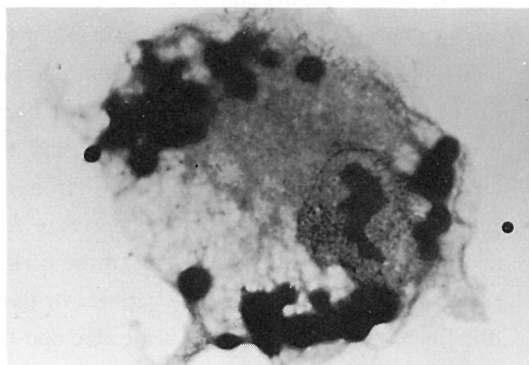


Fig. 4. Phagocytosis of beads by a cultured tumor cell (Giemsa x 500)

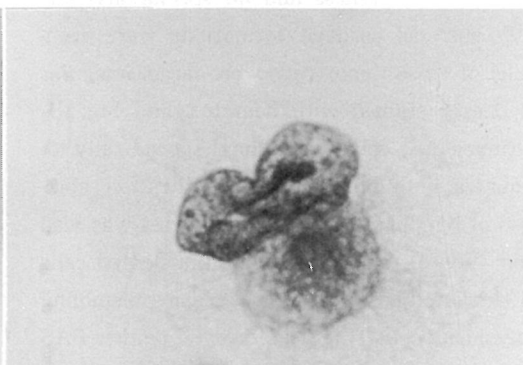


Fig. 5. Lysozyme in a cultured tumor cell (PAP. Counterstain : Hematoxylin x 500)

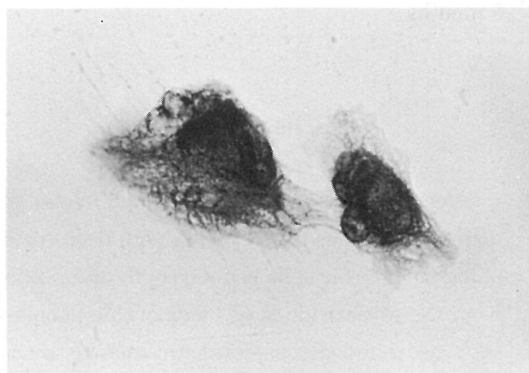


Fig. 6. Vimentin in actively moving tumor cells (Indirect immunoperoxidase. Counterstain : Hematoxylin x 500)

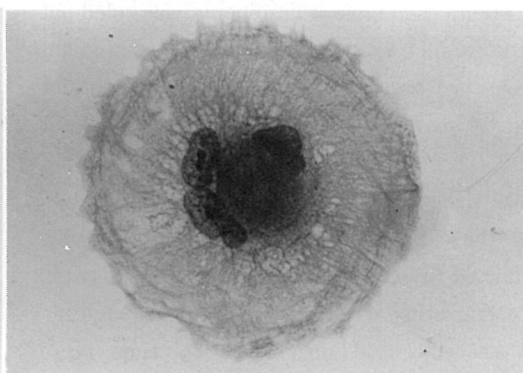


Fig. 7. Vimentin in a cells with poor movements (Indirect immunoperoxidase. Counterstain : Hematoxylin x 500)

with those used in paraffin sections. In addition, indirect immunoperoxidase staining of vimentin (MONOSAN, monoclonal) was also carried out. Anti-mouse IgG conjugated with peroxidase was purchased from Cappel. The tumor cell movements were analyzed by the observation of films of phase-contrast microscopic time lapse cinematography (1 frame/min) which was taken by a Nikon CMF unit using 16mm Kodak plus-X negative films. Phagocytic ability of the tumor cells was tested by adding plastic beads.

Histopathological Findings : H & E preparation demonstrated dispersed large pleomorphic neoplastic cells in the tumor tissue. The tumor cells had poor cohesiveness and no special arrangements such as curlicue formations were seen. Nuclei of these tumor cells were large, irregular and deeply stained with hematoxylin (Fig. 1). Multinucleated cells were found sporadically. A prominent inflammatory cell infiltration composed of lymphocytes and granulocytes was also noted (Fig. 1). Some of the multinucleated cells had elongated eosinophilic cytoplasm resembling to myogenic cells (Fig. 2). However, neither PAS positive glycogen nor PTAH positive myofibrils were detected in the cell bodies. In addition, both myoglobin and keratin were not proven by immunohistochemical method. From these findings, rhabdomyosarcoma or carcinoma was ruled out and the tumor was suspected to be a malignant fibrous histiocytoma though lysozyme was not demonstrated.

Tissue Cultural Findings : As early as 24 hours after the explantation, large pleomorphic cells, similar to those seen in the histological section, were migrating out from the explant. Multinucleated cells were also seen. By time lapse cinematographic analysis, many of the tumor cells were shown to have quite active movements such as pseudopodia formation and ruffling of the peripheral cytoplasm whereas a few of the tumor

cells showed poor movements. The cells with poor movements tended to have flattened cytoplasm and were firmly adhered to the culture dish surfaces (Fig. 3). In addition, multinucleation by cell fusion was also detected (Fig. 3). Phagocytic ingestion of beads were occasionally seen in the tumor cells (Fig. 4). All these findings gave supportive evidences for the diagnosis of malignant fibrous histiocytoma.

Immunohistochemical study revealed presence of lysozyme in the cultured tumor cells (Fig. 6). However, myoglobin and keratin were not present. Vimentin was abundant in all the tumor cells, though the distribution of this filament was different cell by cell. Actively moving cells had very thick cytoplasm and vimentin was heavily aggregated in the perikarya. The calibers of the individual fibers differed each other considerably. In the periphery of the cytoplasm, these fibers were much fewer than in perikaryon and the distribution was uneven (Fig. 6). However, in the cells with poor movements, the fibers were fine and radiating from the perikaryon to the peripheral end of the cytoplasm. The calibers of these fine fibers were almost of the same size and the density was not so different in the perikaryon and in the periphery (Fig. 7).

The above mentioned characters were well preserved in the subcultivated cells during the last 9 months.

Discussion

As pointed out by Enzinger and Weiss (1), malignant fibrous histiocytoma with deep eosinophilic pleomorphic cells is not easy to differentiate from the several kinds of pleomorphic neoplasm such as rhabdomyosarcoma or anaplastic carcinoma merely by routine light microscopic studies. Immunohistochemical methods or electron microscopic studies could give us great facilities for the distinction of these tumors. In this

case, possibility of rhabdomyosarcoma or anaplastic carcinoma was ruled out, since myoglobin and keratin were absent in the tumor cells both in paraffin sections and in cultured cells. In addition, demonstration of histiocytic nature of the tumor cells such as pseudopodia formation and phagocytic activities gave us undoubtful evidence for the diagnosis of malignant fibrous histiocytoma.

Lysozyme was not detected in paraffin embedded sections, but it was demonstrated in the cultured cells. One possible cause of this discrepancy is a new induction of the enzyme in the cultured cells since it is a well known phenomenon that functional differentiation is sometimes induced during the cultivation of certain malignant neoplasms (5, 6). However, it should be taken into consideration that the negative result of this enzyme in the paraffin embedded section might be due to the artificial destruction of the antigenicity during the processing of fixation or embedding since we used neutral formalin for fixation (7).

The intermediate filaments of this tumor cells were composed of vimentin as in many other kinds of mesenchymal tumors (8) and distribution in the actively moving cells were considerably uneven and different each other. This fact seems to be correlated with the dynamic movements or uneven distribution of other two major cytoskeletal components, i. e. actin and microtubules in phagocytic cells (8) since these two elements are closely linked with intermediate filaments such as vimentin (9).

References

1. Enzinger, F. M. & Weiss, S. W. (1983) Malignant

- fibrohistiocytic tumors in "Soft Tissue Tumors" 166-198. Mosby, St. Luis, Tronto, London
2. Ozzello, L., Stout, A. P., & Murray, M. R. (1963) Cultural characteristics of malignant histiocytomas and fibrous xanthomas. *Cancer* 16, 331-344
3. Iwasaki, H., Kikuchi, M., Taki, M. & Enjoji, M. (1982) Benign and Malignant fibrous hitiocytomas of soft tissue -Functional characterization of the cultured cells- *Cancer* 50, 520-530
4. Ozzello, L. & Halmes, J. (1976) The histiocytic nature of dermatofibrosarcoma protuberans : Tissue culture and electron microscopic study. *Am. J. Clin Pathol.* 65, 136-148
5. Parasad, K. N., Mandal, B. & Kumar, S. (1973) Human neuroblastoma cell culture : effect of 5-bromodeoxyuridine on morphological differentiation and levels of neural enzymes. *Proc. Soc. Exp. Biol. Med.* 144, 38-47
6. Goldstein, M. N., Burdman, J. A. & Journey, L. J. (1964) Long term tissue cultures of neuroblastomas II. Evidence for differentiation and maturation. *J. Nat. Cancer Inst.* 32, 165-171
7. Watanabe, K. (1980) Staining Manual of Enzyme immunohistochemistry, in "Enzyme Immunohistochemistry" ed. by Watanabe, K. & Nakane, P. K. 37-45. Gakusai Kikaku, Tokyo
8. Okabe, H., Kusuzaki, K., Takeshita, H., Kuzuhara, H., Kamachi, M., Fujimoto, T., Tsuchihashi, Y. & Ashihara, T. (1984) Studies on giant cell tumor in vitro. *Acta Histochem. Cytochem.* 17, 705
9. Ishikawa, H. (1983) Atlas of Cytoskeleton, 58-82. Kodansha, Tokyo

悪性組織球種の一症例

—腫瘍細胞の組織球的性格の 組織培養による同定—

岡部英俊¹, 芋川 実¹, 越智幸男¹, 国保昌紀²,
林田英資², 友吉唯夫², 竹岡 成³

¹滋賀医科大学附属病院検査部

²滋賀医科大学泌尿器科学教室, ³病理学第一講座

63歳 男性の左後腹膜に発生した巨大な腫瘍中に、大型の多型細胞を認めたが、この腫瘍細胞の培養により、組織球的な特徴、即ち貪食作用や偽足形成を伴う活発な運動性等が確認でき、悪性線維性組織球

種と確定しえたので報告する。また、腫瘍細胞は、胞体に豊富な vimentin 線維を有し、活発な運動を示すものでは、その胞体内分布がきわめて多様であることが認められた。